



Orthognathic surgery and dentofacial orthopedics in adult Class II Division 1 treatment: Mandibular sagittal split osteotomy versus Herbst appliance

Sabine Ruf, DDS, Dr med dent habil,^a and Hans Pancherz, DDS, Odont Dr, FCDSHK (Hon)^b

Bern, Switzerland, and Giessen, Germany

The aim of this study was to assess to what extent adult Herbst treatment is an alternative to orthognathic surgery by comparing the dentoskeletal treatment effects in 46 adult Class II Division 1 subjects treated with a combined orthodontic-orthognathic surgery approach (mandibular sagittal split osteotomy without genioplasty) and 23 adult Class II Division 1 subjects treated with the Herbst appliance. Lateral headfilms in habitual occlusion from before and after treatment (multibracket appliance treatment after surgery or Herbst treatment) were analyzed. All surgery and Herbst subjects were treated successfully to Class I occlusal relationships with normal overjet and overbite. In the surgery group, the improvement in sagittal occlusion was achieved by skeletal more than dental changes; in the Herbst group, the opposite was the case. Skeletal and soft tissue facial profile convexity was reduced significantly in both groups, but the amount of profile convexity reduction was larger in the surgery group. The success and predictability of Herbst treatment for occlusal correction was as high as for surgery. Thus, Herbst treatment can be considered an alternative to orthognathic surgery in borderline adult skeletal Class II malocclusions, especially when a great facial improvement is not the main treatment goal. (*Am J Orthod Dentofacial Orthop* 2004;126:140-52)

In adult subjects having skeletal Class II malocclusions with mandibular deficiency, there traditionally are 2 possible treatment options. The first option is camouflage orthodontics—extracting the maxillary premolars to allow retrusion of the maxillary incisors to normalize the overjet and mask the underlying skeletal problem. The second option is orthognathic surgery to reposition the mandible anteriorly.

In the orthodontic literature, there is little disagreement about which treatment option to choose for mild and severe Class II adults. Mild Class II problems are solved by camouflage orthodontics and severe ones by orthognathic surgery. Disagreement arises, however, in borderline cases, which might be suitable to either treatment option.

Furthermore, clinical practice and research during the last few years have shown that the Herbst appliance

is effective in correcting adult Class II malocclusions.¹⁻⁶ The Herbst appliance can stimulate condylar growth and remodel the glenoid fossa in children and adults.^{3,5} This stimulatory effect on the temporomandibular-joint (TMJ) structures has been also proven histologically in adult Rhesus monkeys treated with the Herbst appliance.⁷ Thus, the Herbst appliance might be an orthopedic tool for nonsurgical, nonextraction treatment in borderline Class II adults.

The aim of this study was to assess the extent of Herbst treatment as an alternative to orthognathic surgery by comparing the dentoskeletal and facial treatment effects in Class II adults treated either with orthognathic surgery (mandibular sagittal split osteotomy without genioplasty) or the Herbst appliance.

MATERIAL AND METHODS

The subjects were 46 adults (38 women, 8 men) treated by orthognathic surgery and 23 adults (19 women, 4 men) treated by the Herbst approach. All patients had Class II Division 1 malocclusions, and all were treated nonextraction. Tooth alignment before and after surgery and after Herbst treatment was performed with multibracket appliances. At the end of treatment, all surgery and Herbst subjects had Class I occlusions with normal overjet and overbite.

^aProfessor and head, Department of Orthodontics, University of Bern, Bern, Switzerland.

^bProfessor and head, Department of Orthodontics, University of Giessen, Giessen, Germany.

Reprint requests to: Prof Dr Sabine Ruf, Klinik für Kieferorthopädie, Universität Bern, Freiburgrstrasse 7, CH-3010 Bern, Switzerland e-mail, sabine.ruf@zmk.unibe.ch.

Submitted, November 2003; revised and accepted, February 2004.
0889-5406/530.00

Copyright © 2004 by the American Association of Orthodontists.
doi:10.1016/j.ajodo.2004.02.011

The mean pretreatment ages were 26 years (15.7-47.6 years) for the surgery subjects and 21.9 years (15.7-44.4 years) for the Herbst patients. Adulthood in the Herbst subjects was defined by the pretreatment hand-wrist radiographic skeletal maturity stages R-II (4 subjects) or R-J (19 subjects) according to Hägg and Taranger.⁸ At the end of treatment, all Herbst subjects had reached the stage R-J. Although no skeletal maturity data existed for the surgery subjects, all were considered to have finished their growth.

The 46 surgery subjects were treated with mandibular advancement with a retromolar sagittal split osteotomy without genioplasty; 23 were treated at the Orthognathic Surgery Clinic in Malmö, Sweden, with a modification of the osteotomy according to Hunsuck⁹ and Epker,¹⁰ and the other 23 were treated at the Orthognathic Surgery Clinic in Minden, Germany, with a modification according to Obwegeser¹¹ and Dal Pont.¹² The Herbst patients were all treated at the Department of Orthodontics, University of Giessen, Germany, with a casted splint Herbst appliance.¹³ Total treatment times averaged 1.7 years for the surgery subjects and 1.8 years for the Herbst subjects.

Lateral headfilms in habitual occlusion from before treatment and after all treatment (after multibracket appliance treatment after surgery and Herbst, respectively) were analyzed. Tracings of the radiographs were made, and linear and angular measurements were taken to the nearest 0.5 mm and 0.5°, respectively. No correction was made for linear enlargement (approximately 8% in the median plane). To reduce the method error, all registrations of the 2 headfilms from each subject were done in the same session. Furthermore, all registrations were done twice with an interval of at least 2 weeks between the registrations. In the final evaluation, the mean value of the registrations was used.

In the surgery subjects, A-point was transferred from the first to the second radiograph after superimposing the headfilms on the stable structures of the anterior cranial base.¹⁴ This procedure was considered valid because all subjects were nongrowing, the surgery was limited to the mandible, and no marked dental changes were expected in the maxilla. In the Herbst subjects, on the other hand, A-point was located on each lateral headfilm, because dental maxillary changes influencing A-point are known to occur.

Cephalometric changes of sagittal and vertical jaw-base relationship, incisor relationship, facial height, facial profile convexity, and lip position were assessed by using standard variables not described in detail. The cephalometric landmarks are shown in Figure 1.

The sagittal-occlusal analysis (SO analysis) of Pancherz¹⁵ was used to analyze the sagittal occlusal

changes during the observation period. For all recordings on the pretreatment and posttreatment radiographs, the occlusal line (OL) (defined by the incisal tip of the most protruded maxillary incisor and the distobuccal cusp of the first permanent maxillary molar) and the occlusal line perpendicular (OLp) through sella from the first headfilm were used as the reference grid. The grid was transferred from the pretreatment to the posttreatment radiograph after superimposing the radiographs on the stable bone structures of the anterior cranial base.¹⁴ The SO analysis comprised the following linear variables (Fig 2):

1. Is/OLp minus Ii/OLp = overjet
2. Ms/OLp minus Mi/OLp = molar relationship (positive value indicates distal relationship; negative value indicates normal or mesial relationship)
3. A/OLp = position of the maxillary jaw base
4. Pg/OLp = position of the mandibular jaw base
5. Is/OLp = position of the maxillary central incisor
6. Ii/OLp = position of the mandibular central incisor
7. Ms/OLp, position of the maxillary permanent first molar
8. Mi/OLp = position of the mandibular permanent first molar

Changes in the different measuring points in relation to OLp during treatment were calculated as after-minus-before differences (D) in landmark position. Variables 3 and 4 describe skeletal changes, and variables 1, 2, and 5 through 8 represent a composite effect of skeletal and dental changes. Variables for dental changes in the maxilla and mandible were obtained by the following calculations (variables 9-12):

9. Is/OLp (D) minus A/OLp (D) = changes in position of the maxillary incisor
10. Ii/OLp (D) minus Pg/OLp (D) = changes in position of the mandibular incisor
11. Ms/OLp (D) minus A/OLp (D) = changes in the position of the maxillary permanent first molar
12. Mi/OLp (D) minus Pg/OLp (D) = changes in the position of the mandibular permanent first molar

An important measure of success and predictability for a certain treatment approach is the consistency of treatment changes. This consistency was calculated as the percentage of subjects exhibiting a certain treatment change larger than or equal to 0.5° or 0.5 mm, respectively.

Statistical methods

For the different variables, the arithmetic mean (mean) and the standard deviation (SD) were calculated.

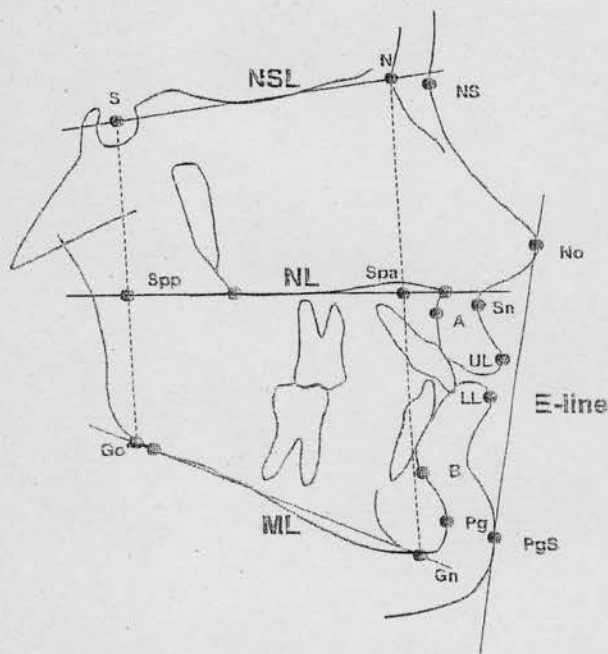


Fig 1. Reference points and lines used in standard cephalometric analysis.

Student *t* tests for unpaired samples were performed to assess possible differences between the 2 surgical approaches (Swedish and German samples) as well as between the surgery and Herbst groups. Student *t* tests for paired samples were performed to assess the significance of treatment changes in the surgery and Herbst groups. The statistical significance was determined at the 0.1%, 1%, and 5% levels of confidence. A level larger than 5% was considered statistically not significant.

The method error of the double registrations (tracings and measurements from before and after treatment roentgenograms) of all subjects was calculated by using the formula of Dahlberg:¹⁶

$$ME = \sqrt{\frac{\sum d^2}{2n}}$$

where *d* is the difference between 2 measurements of a pair and *n* is the number of subjects. The maximum method error for dental changes was 1.0 mm. For skeletal and soft tissue changes, the method error did not exceed 0.7 mm for linear variables, 1.0° for angular variables, and 1.2 for index variables.

RESULTS

Because of the small number of men in the surgery (*n* = 8) and the Herbst (*n* = 4) groups as well as the identical relative frequency (17%) of men in the 2 groups, sex

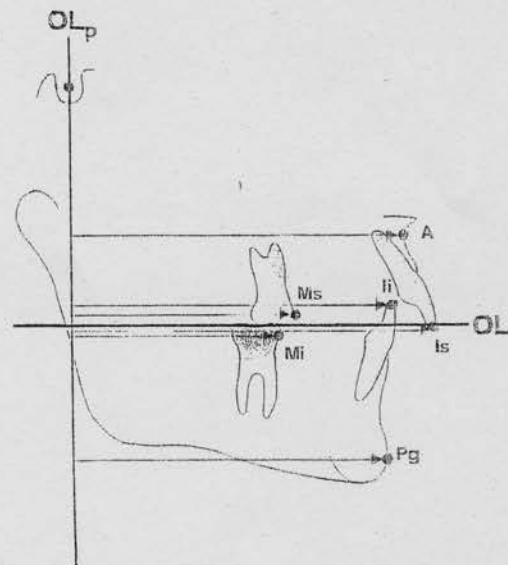


Fig 2. OL/OLp reference grid and measuring landmarks used in cephalometric analysis of sagittal occlusal changes (SO analysis).

differences were not considered. Thus, the male and females samples in each treatment group were pooled.

Because the comparison of the treatment effects of the 2 modifications of the retromolar sagittal split osteotomy (Hunsuck/Epker and Obwegeser/Dal Pont) showed no statistically significant differences, the 2 surgery samples were evaluated as 1 group.

The cephalometric records of the surgery and Herbst groups before and after treatment are shown in Tables I and II. With respect to the cephalometric standard variables (Table I) from before treatment, the surgery group compared with the Herbst group had a larger Wits value (mean 2.2 mm; *P* < .01), a larger posterior facial height index (mean 5.5; *P* < .001), a smaller interjaw-base angle (mean 5.5; *P* < .01), and a larger soft tissue profile convexity including the nose (mean 4.9; *P* < .001). With respect to the variables of the SO analysis (Table II) from before treatment, no statistically significant differences between the surgery and the Herbst groups were found.

Standard cephalometric treatment changes

The treatment changes in the surgery and Herbst groups are shown in Table III. The changes in sagittal maxillary position (SNA) were comparable in both groups. The surgery group had greater mandibular advancement (SNB, mean 1.3°.

Table 1. Cephalometric standard records (mean, SD) before and after treatment in 46 adults treated with orthognathic surgery (mandibular sagittal split osteotomy) followed by multibracket appliance and 23 adults treated with Herbst appliance followed by multibracket appliance

Variable		Surgery				Herbst			
		Before		After		Before		After	
		Mean	SD	Mean	SD	Mean	SD	Mean	SD
Sagittal jaw relation	SNA (°)	81.41	4.01	81.12	3.89	80.46	3.23	80.57	3.27
	SNB (°)	75.37	3.39	77.49	3.41	75.27	4.06	76.09	4.19
	SNPg (°)	77.08	3.75	78.68	3.80	76.84	4.28	77.54	4.58
	ANB (°)	6.04	2.75	3.62	2.73	5.18	1.69	4.48	1.79
	ANPg (°)	4.33	3.46	2.44	3.19	3.62	2.30	3.02	2.45
Vertical jaw relation	Wits (mm)	4.72	3.01	0.61	3.36	2.55	2.06	1.47	1.95
	ML/NSL (°)	30.08	7.82	33.41	7.86	34.12	8.61	33.43	8.97
	NL/NSL (°)	8.77	2.91	8.39	3.57	7.29	3.15	6.77	3.61
Incisor relation	ML/NL (°)	21.31	7.34	25.02	7.78	26.83	7.91	26.72	7.72
	Overbite (mm)	4.23	2.84	2.16	0.94	4.43	1.83	1.95	0.68
Facial height	Spa-Gn × 100/N-Gn (index)	54.84	2.34	56.11	2.58	54.55	1.83	54.97	1.74
	Spp-Go' × 100/S-Go' (index)	46.89	4.89	44.88	5.64	41.40	5.26	42.43	5.18
Profile convexity	NAPg (°)	170.87	7.33	175.32	6.79	172.08	5.21	173.17	5.42
	NS/Sn/PgS (°)	158.12	6.71	163.57	6.71	159.68	6.25	162.82	6.79
	NS/No/PgS (°)	121.35	4.22	124.55	4.50	126.30	3.93	127.34	4.32
Lip position	UL-E-line (mm)	-2.55	2.84	-5.05	2.87	-3.11	2.28	-4.37	2.49
	LL-E-line (mm)	-1.67	3.27	-2.79	3.38	-1.64	3.28	-1.90	3.02

Table 2. SO analysis. Cephalometric records (mean, SD) before and after treatment in 46 adult Class II Division 1 subjects treated with orthognathic surgery (mandibular sagittal split osteotomy) followed by multibracket appliance and 23 adult Class II Division 1 subjects treated with Herbst appliance followed by multibracket appliance

Variable (mm)	Surgery				Herbst			
	Before		After		Before		After	
	Mean	SD	Mean	SD	Mean	SD	Mean	SD
1. Overjet	9.69	2.68	3.38	1.13	8.88	2.66	2.13	0.61
Is/OLp-li/OLp								
2. Molar relation*	+1.77*	1.97	-3.23*	3.00	+1.53*	1.35	-2.58*	0.98
Ms/OLp-Mi/OLp								
3. Maxillary base	78.89	4.80	78.89	4.80	78.52	3.99	78.91	3.77
A/OLp								
4. Mandibular base	77.67	5.54	81.72	5.97	80.07	4.94	81.35	4.77
Pg/OLp								
5. Maxillary incisor	88.36	5.11	86.99	5.59	88.21	4.47	85.42	4.80
Is/OLp								
6. Mandibular incisor	78.66	5.41	83.61	5.81	79.33	5.36	83.29	4.88
li/OLp								
7. Maxillary molar	56.37	5.51	57.06	5.71	57.78	4.70	56.35	4.68
Ms/OLp								
8. Mandibular molar	54.60	5.95	60.29	6.65	56.25	5.32	58.92	4.97
Mi/OLp								

*Plus (+) implies Class II molar relationship; minus (-) implies Class I molar relationship.

$P < .001$; SNPg, mean 0.9° , $P < .01$) and consequently greater decreases in sagittal jaw-base relationship angles (ANB, mean 1.7° , $P < .001$; SNPg, mean 1.3° , $P < .001$). The Wits appraisal showed a

larger reduction in the surgery than in the Herbst group (Wits mean, 3.0° , $P < .001$).

The amount of overbite reduction was comparable for the surgery and Herbst subjects. The mandibular

Table III. Standard cephalometrics. Comparison of treatment changes (mean, SD) in 46 adult Class II Division 1 subjects treated with orthognathic surgery (mandibular sagittal split osteotomy) followed by multibracket appliance and 23 adult Class II Division 1 subjects treated with Herbst appliance followed by multibracket appliance

Variable		Treatment changes (after-before)							
		Surgery			Herbst			Surgery-Herbst	
		Mean	SD	t	Mean	SD	t	Mean	t
Sagittal jaw relation	SNA (°)	-0.29	1.13	-1.72 ^{ns}	0.11	0.64	0.82 ^{ns}	-0.40	-1.14 ^{ns}
	SNB (°)	2.12	1.31	10.98 [†]	0.82	0.78	5.03 [†]	1.30	4.33 [†]
	SNP _g (°)	1.60	1.31	8.25 [†]	0.70	0.85	3.96 [†]	0.90	2.90 [†]
	ANB (°)	-2.41	1.29	-12.71 [†]	-0.70	0.77	-4.33 [†]	-1.71	-5.70 [†]
	ANP _g (°)	-1.89	1.33	-9.50 [†]	-0.60	0.87	-3.28 [†]	-1.29	-4.03 [†]
Vertical jaw relation	Wits (mm)	-4.11	1.90	-14.64 [†]	-1.08	1.26	-4.12 [†]	-3.03	-6.73 [†]
	ML/NSL (°)	3.33	2.48	9.12 [†]	-0.69	1.27	-2.61 ^{ns}	4.02	7.05 [†]
	NL/NSL (°)	-0.38	1.73	-1.47 ^{ns}	-0.52	1.45	-1.73 ^{ns}	0.14	0.32 ^{ns}
Incisor relation	ML/NL (°)	3.71	2.63	9.54 [†]	-0.11	1.59	-0.33 ^{ns}	3.00	4.91 [†]
	Overbite (mm)	-2.06	2.56	-5.43 [†]	-2.48	1.94	-6.14 [†]	0.42	0.68 ^{ns}
Facial height	Spa-Gn × 100/N-Gn (index)	1.27	0.92	9.36 [†]	0.42	0.73	2.75 [*]	0.85	3.70 [†]
	Spp-Go' × 100/S-Go' (index)	-2.01	2.51	-5.43 [†]	1.03	1.45	3.41 [†]	-3.05	-5.17 [†]
Profile convexity	NAP _g (°)	4.45	2.80	10.78 [†]	1.09	1.58	3.31 [†]	3.36	5.17 [†]
	NS/Sn/PgS (°)	5.45	3.37	10.97 [†]	3.14	1.79	8.39 [†]	2.31	2.96 [†]
	NS/No/PgS (°)	3.20	2.67	8.12 [†]	1.04	1.97	2.54 [*]	2.16	3.32 [†]
Lip position	UL-E-line (mm)	-2.49	1.74	-9.73 [†]	-1.26	1.07	-5.64 [†]	-1.23	-3.00 [†]
	LL-E-line (mm)	-1.12	2.33	-3.26 [*]	-0.26	1.10	-1.12 ^{ns}	-0.86	-1.62 ^{ns}

ns implies $P > .05$ (not significant).

*implies $P < .05$.

†implies $P < .01$.

‡implies $P < .001$.

plane angle showed opposite changes in the 2 treatment groups. In the surgery group, the ML/NSL increased (mean 3.3°, $P < .001$), whereas a decrease (mean 0.7°, $P < .05$) was noted in the Herbst group. The interjaw-base angle (ML/NL) increased in the surgery group (mean 3.7°, $P < .001$) and decreased in the Herbst group (mean 0.1°, not significant). The inclination of the maxilla in relation to the anterior cranial base (NL/NSL) was unaffected by either surgery or Herbst treatment.

Anterior facial height increased more in the surgery group than in the Herbst group (index mean 0.8, $P < .001$). Similar to the changes of the mandibular plane angle, the posterior facial height showed opposite changes in the 2 groups. A reduction in posterior facial height took place in the surgery group (index mean 2.0, $P < .001$), whereas an increase was seen in the Herbst group (index mean 1.0; $P < .01$).

The amount of profile convexity reduction was larger in the surgery group than in the Herbst group. The largest group difference (mean 3.4°) was found for skeletal profile convexity (NAP_g, mean 3.4°, $P < .001$) and the smallest for soft tissue profile convexity including the nose (NS/No/PgS, mean 2.2°, $P < .01$).

The positions of the upper and lower lips became

more retrusive in both treatment groups. A statistically significant group difference was found only for the upper lip (UL-E-line), which became more retrusive (1.2 mm, $P < .01$) in the surgery group.

SO analysis treatment changes

The treatment changes in the surgery and Herbst groups are shown in Table IV. The amounts of overjet reduction (surgery, 6.3 mm; Herbst, 6.7 mm), Class II molar correction (surgery, 5.0 mm; Herbst, 4.1 mm), and mandibular molar mesialization (surgery, 1.6 mm, Herbst, 1.4 mm) were comparable in the 2 groups. The surgery group had greater (mean 2.8 mm, $P < .001$) mandibular advancement than the Herbst group. In comparison with the surgery group, the Herbst group showed greater maxillary base forward development (mean 0.4 mm; $P < .001$), maxillary incisor retrusion (mean 1.8 mm, $P < .01$), and mandibular incisor protrusion (mean 1.8 mm; $P < .01$). The maxillary molars moved in opposite directions in the 2 groups. A mesial movement of the maxillary molars was found in the surgery group (mean 0.7 mm, $P < .05$), and a distal movement was seen in the Herbst group (mean 1.8 mm, $P < .001$).

The relationship between dental and skeletal

Table IV. SO-Analysis. Comparison of treatment changes (mean, SD) in 46 adult Class II Division 1 subjects treated with orthognathic surgery (mandibular sagittal split osteotomy) followed by multibracket appliance and 23 adult Class II Division 1 subjects treated with Herbst appliance followed by multibracket appliance

Variable (mm)	Treatment changes (after-before)							
	Surgery			Herbst			Surgery-Herbst	
	Mean	SD	t	Mean	SD	t	Mean	t
1. Overjet Is/OLp(D)-Ii/OLp(D)	-6.31	2.46	-17.40 [‡]	-6.75	2.63	-12.30 [‡]	0.44	0.66 ^{ns}
2. Molar relation Ms/OLp(D)-Mi/OLp(D)	-5.00	3.13	-10.84 [‡]	-4.11	1.45	-13.61 [‡]	-0.89	-1.25 ^{ns}
3. Maxillary base A/OLp(D)	0	0	0 ^{ns}	0.39	0.65	2.88 [†]	-0.39	-3.90 [‡]
4. Mandibular base Pg/OLp(D)	4.05	2.49	11.03 [‡]	1.28	1.25	4.91 [‡]	2.77	4.86 [‡]
9. Maxillary incisor Is/OLp (D)-A/OLp (D)	-1.36	2.21	4.17 [‡]	-3.17	2.11	-7.21 [‡]	1.81	3.30 [†]
10. Mandibular incisor Ii/OLp(D)-Pg/Olp(D)	0.90	2.36	2.56 [†]	2.69	1.93	6.67 [‡]	-1.79	-3.03 [†]
11. Maxillary molar Ms/OLp(D)-A/OLp(D)	0.69	1.99	2.35 [*]	-1.83	1.10	-7.95 [‡]	2.52	5.48 [‡]
12. Mandibular molar Mi/OLp(D)-Pg/OLp(D)	1.64	2.02	5.51 [†]	1.39	1.14	5.85 [‡]	0.25	0.51 ^{ns}

ns implies $P > 0.05$ (not significant).

*implies $P < 0.05$.

†implies $P < 0.01$.

‡implies $P < 0.001$.

changes contributing to Class II correction in the incisor and molar regions is shown in Figure 3. In the Herbst group, the improvement in sagittal occlusion was achieved by dental more than skeletal changes; in the surgery group, the opposite was the case. The amount of skeletal changes contributing to overjet and molar correction was larger in the surgery (63% and 80%, respectively) than in the Herbst (13% and 22%, respectively) group.

Individual changes

The individual changes for 8 of the 25 analyzed cephalometric variables are given in Figure 4. All variables had substantial interindividual variation in both the groups.

The maximum amounts of changes in individual subjects of the 2 groups are given in Table V. The largest amount of overjet reduction was in a Herbst subject (12.2 mm). For all other variables, the maximum amount of individual changes was noted in the surgery subjects. Even if the amount of changes differed between the groups, the direction of changes was the same, except for the mandibular plane angle and posterior facial height.

The consistency of treatment reaction is given in Table V. Overjet and overbite were reduced consis-

tently in both the surgery (98% for both variables) and the Herbst (100% and 96%, respectively) subjects; 100% of the Herbst and 93% of the surgery subjects had improved molar relationships. Mandibular prognathism increased more consistently in the surgery (SNB = 91%) than in the Herbst (SNB = 74%) subjects. Correspondingly, more patients with an ANB reduction were seen in the surgery than in the Herbst (98% and 74%, respectively) groups. The vertical jaw-base relationship and the anterior and posterior facial heights were more consistently affected by surgery (91% increase, 87% increase, and 78% decrease, respectively) than by Herbst treatment (56% decrease, 52% increase, and 65% increase, respectively). Skeletal profile convexity and soft tissue profile convexity including and excluding the nose were reduced more consistently in the surgery (91%, 96%, and 76%, respectively) than in the Herbst (70%, 96%, and 83%, respectively) subjects.

The skeletofacial changes during treatment are shown for 2 surgery subjects (Figs 5 and 6) and 2 Herbst subjects (Figs 7 and 8).

DISCUSSION

The subjects in this investigation can be considered to be unselected. The Swedish and German samples included all Class II Division 1 subjects (except those

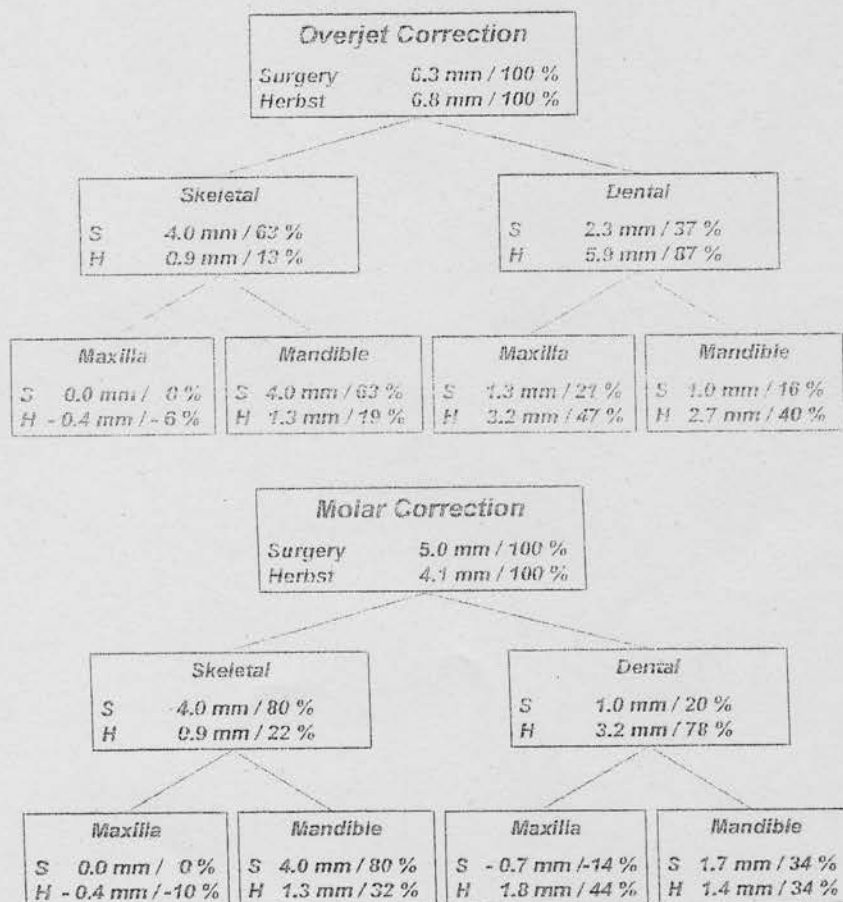


Fig 3. Mechanism of overjet and molar correction in 46 Class II Division 1 adults treated with orthognathic surgery (mandibular sagittal split osteotomy) followed by multibracket appliances and 23 Class II Division 1 adults treated with Herbst appliances followed by multibracket appliances.

with severe open bite) treated during 10 years. The Herbst sample comprised consecutive Class II Division 1 adults treated with the Herbst appliance at the orthodontic department in Giessen.

There was a clear overrepresentation of women in both samples. This agrees with earlier studies of adult orthodontic and orthognathic surgery patients.¹⁷⁻²¹ The reason for this unequal sex distribution is unknown, but it might be associated with women's greater interest in improving their facial and dental appearance.²²

For the pretreatment cephalometric parameters, the surgery group had a significantly larger posterior facial height and a smaller interjaw-base angle. Thus, considering the vertical jaw-base relationship, the surgery subjects had slightly better pretreatment conditions for Class II correction than did the Herbst subjects.^{23,24} On the other hand, the Wits appraisal and the soft tissue profile convexity including the nose were significantly larger in the surgery group. Therefore, from the sagittal

discrepancy point of view, the surgery group had slightly more severe pretreatment conditions.

All subjects in both groups were treated successfully to a Class I occlusal relationship. The amount of overjet reduction was greatest in the Herbst subjects. This was true when comparing group averages and looking at the maximum individual overjet reduction. Proffit et al²⁵ stated that orthodontic treatment was likely to fail (even in adolescents when growth assists Class II correction) if the overjet exceeds 10 mm. In our Herbst sample, however, larger overjet reductions (maximum reduction, 12.2 mm) were found. Average overbite reduction also was larger in the Herbst than in the surgery group, whereas Class II molar correction was, on average, slightly more pronounced in the surgery group.

Even though Class II correction was very successful in the Herbst patients, the mechanism behind it was different from that in the patients treated with orthog-

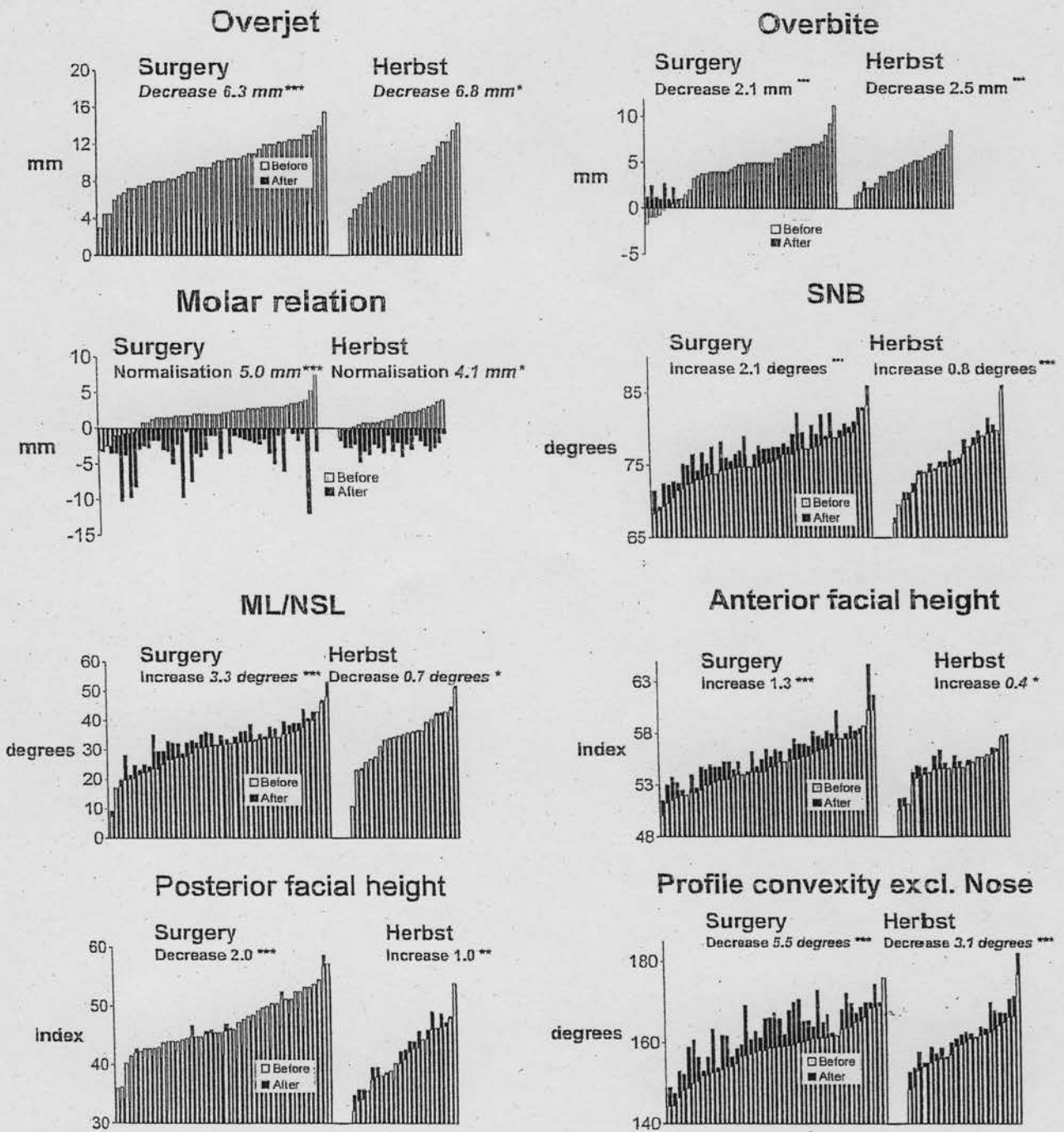


Fig 4. Individual treatment changes of overjet, overbite, molar relation, SNB angle, ML/NSL angle, anterior facial height, posterior facial height, and profile convexity excluding nose in 46 Class II Division 1 adults treated with orthognathic surgery (mandibular sagittal split osteotomy) followed by multibracket appliances and 23 Class II Division 1 adults treated with Herbst appliances followed by multibracket appliances.

nathic surgery. Both the standard cephalometric records and the SO analysis showed that the Class II malocclusions in the Herbst subjects were corrected by dental more than skeletal changes; in the surgery subjects, the

opposite was the case. This finding agrees with previous studies comparing the treatment effects of orthodontics and orthognathic surgery in adults.^{17,21}

The most profound difference between the surgery

Table V. Maximum individual cephalometric treatment changes and consistency of treatment changes (%) in 46 adult Class II Division 1 subjects treated with orthognathic surgery (mandibular sagittal split osteotomy) followed by multibracket appliance and 23 adult Class II Division 1 subjects treated with Herbst appliance followed by multibracket appliance

Variable		Treatment changes (after-before)			
		Surgery		Herbst	
		Maximum	Consistency %	Maximum	Consistency %
Incisor relation	Overjet (mm)	-11.75	98	-12.25	100
	Overbite (mm)	-9.50	98	-6.25	96
Molar relation*	(mm)	-16.00	93	-6.25	100
Sagittal jaw relation	SNB (°)	5.25	91	2.25	74
	ANB (°)	-5.25	98	-3.00	74
Vertical jaw relation	ML/NSL (°)	11.75	91	-2.75	56
	Spa-Gn × 100/N-Gn (index)	4.50	87	1.85	52
Facial height	Spp-Go' × 100/S-Go' (index)	-11.50	78	3.13	65
	NAPg (°)	12.00	91	4.75	70
Profile convexity	NS/Sn/PgS (°)	12.50	96	7.50	96
	NS/No/PgS (°)	9.75	76	4.00	83

*minus (-) implies normalization

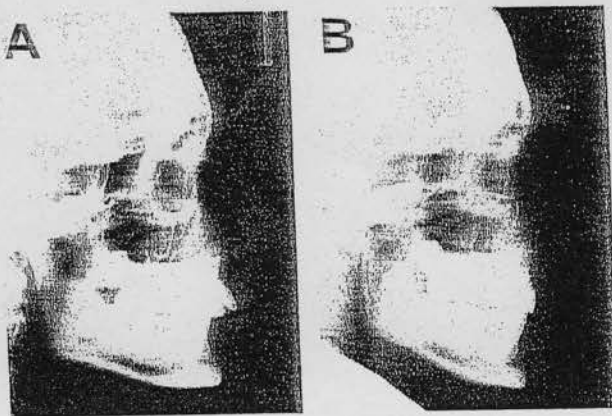


Fig 5. A, Pretreatment and B, posttreatment lateral headfilms of 33-year-old female surgery subject (mandibular sagittal split osteotomy).

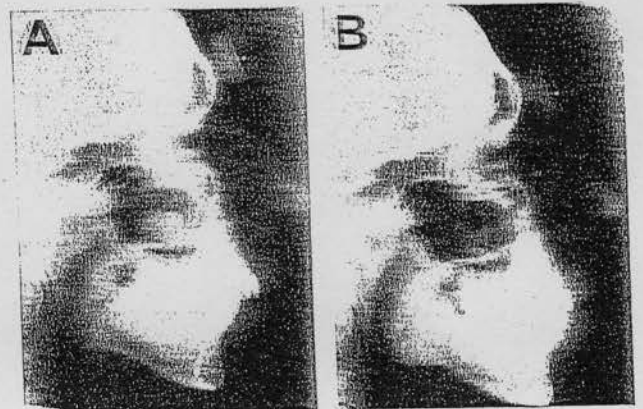


Fig 6. A, Pretreatment and B, posttreatment lateral headfilms of 22-year-old male surgery subject (mandibular sagittal split osteotomy).

and the Herbst subjects was the greater mandibular base advancement (SNB, SNP_g, Pg/OLp), resulting in larger reductions of the ANB angle, the Wits appraisal, and the skeletal and soft tissue profile convexities in the surgery group. The greater upper lip retrusion in the surgery group was most likely due to the larger mandibular base advancement in those subjects. As a result of the mandibular advancement, the reference line (esthetic line) automatically became more anteriorly positioned, thus resulting in a relative lip retrusion.

Other marked differences between the 2 treatment groups were the direction in changes of the mandibular plane angle and posterior facial height. Although a larger increase in posterior facial height than in anterior

facial height (resulting in a reduction in the mandibular plane angle) was noted in the Herbst group, the opposite was true in the surgery group. Because the pretreatment mandibular plane angle of the surgery group was normal,²⁶ the increase in the angle must be considered unfavorable in Class II treatment. The angular increase in the surgery subjects was most probably due to bone remodeling in the gonion area. This remodeling has been shown to continue long after surgery.^{20,27} Possible causes are an inadequate overlap between the 2 bony fragments at the time of surgery,^{28,29} the partial detachment of the elevator muscles from the gonion area (operation according to Obwegeser/Dal Pont only) and their subsequent reattachment and adaptation,²⁷ the

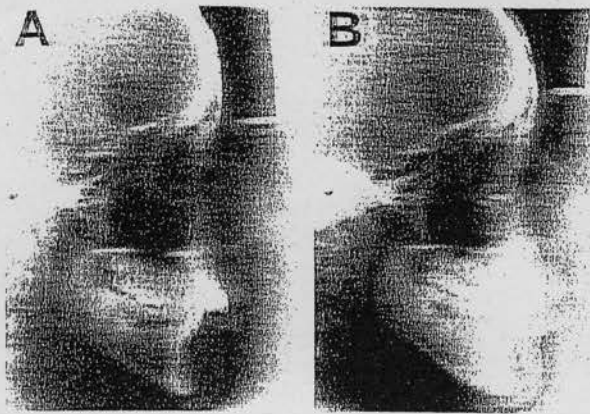


Fig 7. A, Pretreatment and B, posttreatment lateral headfilms of 19-year-old female Herbst subject.

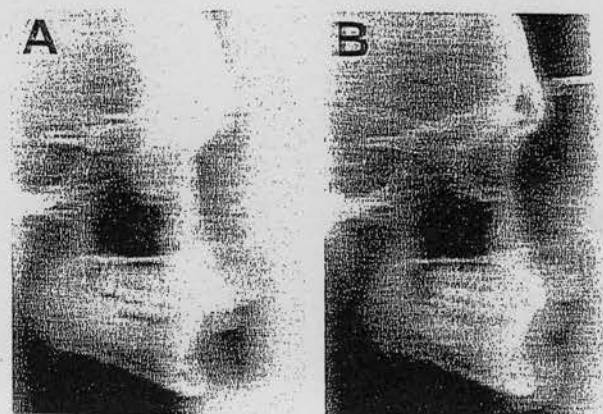


Fig 8. A, Pretreatment and B, posttreatment lateral headfilms of 20-year-old male Herbst subject.

general postsurgical adaptive processes of all soft tissues, tendons, and muscles that have been directly or indirectly affected by the surgical jaw displacement,^{27,30,31} and the possible condylar resorption that has been reported rather frequently in orthognathic surgery patients,^{17,27} especially in those with a pretreatment internal derangement of the TMJ.³²

The direction of maxillary molar movements differed between the 2 treatment groups. Although the distal movement of the maxillary molar in the Herbst group was to be expected from the headgear effect of the appliance,³³ the mesial movement of the maxillary molars in the surgery group was unexpected because all subjects were treated nonextraction. Even if decreases in maxillary and mandibular arch lengths in adulthood occur,³⁴ the amounts of change in the surgery subjects were larger than those normally reported to occur over 1 decade. A possible explanation for the mesial movement of the maxillary molars is a transverse maxillary expansion most likely performed in most of the patients during the presurgical orthodontic phase. The space gained by this expansion might have been reciprocally closed, leading to the observed retrusion of the maxillary incisors (1.4 mm) and the mesial movement of the maxillary molars (0.7 mm).

The consistency in treatment reaction was larger for the surgery group than for the Herbst group for variables directly or indirectly affected by the amount of mandibular advancement (SNB, ANB, skeletal profile convexity). On the other hand, the reduction in soft tissue profile convexity excluding the nose was the same (96%) in both groups, whereas, for the reduction of the soft tissue profile convexity including the nose, the consistency was larger in the Herbst subjects. Furthermore, for the Class II corrective variables (overjet, overbite, molar relationship), no marked group

differences were detected. Therefore, the predictability of the treatment outcome in terms of consistency of changes was, on average, comparable for both groups. This agrees with the findings of Tulloch et al,³⁵ who concluded that the success rate of overjet reduction was only slightly higher for orthodontic than for surgical treatment irrespective of age and malocclusion severity.

Thus, the question arises which is the best treatment modality for a borderline Class II adult. Even when the knowledge from this study is added to what is known from the literature, there seems to be no single, conclusive answer to the question. Several factors must be considered in the treatment decision process: (1) the reason the patient is seeking treatment; (2) the effects that can be provided by Herbst treatment and orthognathic surgery, respectively; and (3) the costs and risks of the 2 treatment approaches.

There is agreement in the literature that the main reasons for adults seeking treatment are dental and facial esthetics as well as stomatognathic or functional improvement.³⁶⁻³⁸ Patients with severe skeletal Class II malocclusions are more motivated to undergo orthodontic than surgical treatment.³⁸ This is not surprising because most people prefer the least invasive measure to solve their problems. Interestingly, the type of treatment selected (surgery or orthodontics) depends mainly on the subject's self-perception of his or her facial profile and is not associated with the degree of dentoskeletal discrepancy. This means that the more dissatisfied the patients are with their facial esthetics, the more likely they are to choose surgery.^{39,40} However, after treatment, surgical and orthodontic patients were equally satisfied with their profile changes.^{17,20}

In our study, larger reductions in profile convexity were found in the surgery group than in the Herbst group. In contrast, Shell and Woods⁴¹ found that,

regardless of whether Class II patients were treated with growth modification during adolescence or orthognathic surgery during adulthood, facial esthetics improved to a similar extent. Furthermore, the reduction in facial profile convexity achieved by Herbst treatment seems not to be age-dependent.⁴

Even if the occlusion can be corrected very successfully by adult Herbst treatment, chin projection and thus facial esthetics might be not be optimal after therapy. If, however, chin prominence is the main problem for the patient, advancement genioplasty offers a less costly, less risky alternative to enhance facial esthetics than a mandibular sagittal split osteotomy.^{42,43}

Even though stomatognathic or functional improvement is the second most frequent reason for adults to seek treatment, little is known about the changes in masticatory function after orthognathic surgery. For Class III patients, scientific data show no significant improvement in postoperative masticatory function.⁴⁴ For Class II patients, on the other hand, at least to our knowledge, no such data exist.

Although there is controversy about the effect of orthognathic surgery on TMJ function, recent data⁴⁵ seem to support the view that patients with preexisting articular disc displacements undergoing mandibular advancement surgery are likely to have a significant worsening of the TMJ dysfunction problem postsurgery. No comparable data exist for adult Herbst treatment. However, in a group of Herbst subjects that included 8 of the present adults, TMJ function was found to improve during treatment.⁴⁶

When looking at the costs of combined orthodontic-orthognathic surgery treatment, 60%-75% are due to the surgical part.⁴⁷⁻⁴⁹ Therefore, a remarkable cost reduction in adult Class II treatment can be achieved with the Herbst appliance instead of orthognathic surgery.

The most common surgical risk of mandibular advancement is neurosensory disturbances of the lower lip that affect about 50% of the subjects.⁵⁰ Additionally, nonunion or mal-union of the bony fragments, bad splits,⁵¹ and condylar resorption^{17,32} are frequent complications. Even if neurosensory disturbances of the lip occur after genioplasty alone, the prevalence is significantly lower than with mandibular sagittal split or a combination of sagittal split and genioplasty.⁵²

A main complication in orthodontics is root resorption. The amount of root resorption has been found to correlate with the amount of overjet reduction and horizontal tooth movement.⁵³ Furthermore, extensive palatal root torque, which is likely to be applied during orthodontic Class II treatment, has been shown to be a predisposing factor for root resorption of the mandib-

ular incisors.⁵⁴ Thus, when comparing surgery and dentofacial orthopedics (Herbst appliance), the risks associated with surgery are obviously much greater. Finally, the failure rate of surgical Class II treatment is higher than that for a dentofacial orthopedic/orthodontic approach.³⁵ Therefore, the important question in treatment planning is whether the greater improvement in facial esthetics accomplished by orthognathic surgery compared with dentofacial orthopedics with the Herbst appliance is worth the increased costs and risks of the surgical approach.

CONCLUSIONS

The Herbst appliance is a powerful tool for nonsurgical, nonextraction treatment of adult Class II malocclusions. Thus, the treatment approach can be considered as an alternative to orthognathic surgery in borderline skeletal Class II subjects. For Class II correction, the success rate and predictability of Herbst treatment is as high as for orthognathic surgery. If, however, the patient's main wish is a greatly improved facial profile, orthognathic surgery is the better treatment alternative.

We thank the Orthognathic Surgery Department in Malmö, Sweden, and Drs Witschel and Wrede in Bad Oeynhausen, Germany, for providing access to the clinical records and the lateral headfilms of the surgery subjects.

REFERENCES

1. Pancherz H. Dentofacial orthopedics or orthognathic surgery: is it a matter of age? *Am J Orthod Dentofacial Orthop* 2000;117:571-4.
2. Pancherz H, Ruf S. The Herbst appliance—research based updated clinical possibilities. *World Orthod J* 2000;1:17-31.
3. Ruf S, Pancherz H. Kiefergelenkwachstumsadaptation bei jungen Erwachsenen während Behandlung mit der Herbst-Apparatur. Eine prospektive magnetresonanztomographische und kephalometrische Studie. *Inf Orthod Kieferorthop* 1998;30:735-50.
4. Ruf S, Pancherz H. Dentoskeletal effects and facial profile changes in young adults treated with the Herbst appliance. *Angle Orthod* 1999;69:239-46.
5. Ruf S, Pancherz H. Temporomandibular joint remodeling in adolescents and young adults during Herbst treatment: a prospective longitudinal magnetic resonance imaging and cephalometric radiographic investigation. *Am J Orthod Dentofacial Orthop* 1999;115:607-18.
6. Ruf S, Pancherz H. When is the ideal period for Herbst therapy—early or late? *Semin Orthod* 2003;9:47-56.
7. McNamara JA, Peterson JE, Pancherz H. Histologic changes associated with the Herbst appliance in adult rhesus monkeys (*Macacca mulatta*). *Semin Orthod* 2003;9:26-40.
8. Hägg U, Taranger J. Skeletal stages of the hand and wrist as indicators of the pubertal growth spurt. *Acta Odontol Scand* 1980;38:187-200.

9. Hunsuck EE. A modified intraoral sagittal splinting technique for correction of mandibular prognathism. *J Oral Surg* 1968;26:250-3.
10. Epker BN. Modifications in the sagittal osteotomy of the mandible. *J Oral Surg* 1977;35:157-9.
11. Obwegeser H. The surgical correction of mandibular prognathism and retrognathia with consideration of genioplasty. *Oral Surg* 1957;10:677-89.
12. Dal Pont G. Retromolar osteotomy for the correction of prognathism. *J Oral Surg* 1961;19:42-7.
13. Pancherz H. The Herbst appliance. Sevilla, Spain: Editorial Aguiram; 1995.
14. Björk A, Skieller V. Normal and abnormal growth of the mandible. A synthesis of longitudinal cephalometric implant studies over a period of 25 years. *Eur J Orthod* 1983;5:1-46.
15. Pancherz H. The mechanism of Class II correction in Herbst appliance treatment. A cephalometric investigation. *Am J Orthod* 1982;82:104-13.
16. Dahlberg G. Statistical methods for medical and biological students. New York: Interscience Publications; 1940.
17. Cassidy DW, Herbosa EG, Rotskoff KS, Johnston LE. A comparison of surgery and orthodontics in "borderline" adults with Class II Division 1 malocclusions. *Am J Orthod Dentofacial Orthop* 1993;104:455-70.
18. Gerzanic L, Jagsch R, Watzke IM. Psychologic implications of orthognathic surgery in patients with skeletal Class II or Class III malocclusion. *Int J Adult Orthod Orthognath Surg* 2002;17:75-81.
19. Lawrence TN, Ellis E, McNamara JA. The frequency and distribution of skeletal and dental components in Class II orthognathic surgery patients. *J Oral Maxillofac Surg* 1985;43:24-34.
20. Mihalik CA, Proffit WR, Phillips C. Long-term follow-up of Class II adults treated with orthodontic camouflage: a comparison with orthognathic surgery outcomes. *Am J Orthod Dentofacial Orthop* 2003;123:266-78.
21. Proffit WR, Phillips C, Douvartzidis N. A comparison of outcomes of orthodontic and surgical-orthodontic treatment of Class II malocclusion in adults. *Am J Orthod Dentofacial Orthop* 1992;101:556-65.
22. Hoppenreijts TJ, Hakman EC, van't Hof MA, Stoelinga PJ, Tuinzing DB, Freihofer HP. Psychologic implications of surgical orthodontic treatment in patients with anterior open bite. *Int J Adult Orthod Orthognath Surg* 1999;14:101-12.
23. Hirzel HG, Grewe JM. Activators: a practical approach. *Am J Orthod* 1974;66:557-70.
24. Skieller V, Björk A, Linde Hansen T. Prediction of mandibular growth rotation evaluated from a longitudinal implant sample. *Am J Orthod* 1984;86:359-70.
25. Proffit WR, Phillips C, Tulloch JFC, Medland PH. Surgical versus orthodontic correction of skeletal Class II malocclusion in adolescents: effects and indications. *Int J Adult Orthod Orthognath Surg* 1992;7:209-20.
26. Bathia SN, Leighton BC. A manual of facial growth. A computer analysis of longitudinal growth data. Oxford: Oxford University Press; 1993.
27. Schubert P, Bailey LTJ, White RP, Proffit WR. Long-term cephalometric changes in untreated adults compared to those treated with orthognathic surgery. *Int J Adult Orthod Orthognath Surg* 1999;14:91-9.
28. Kohn MW. Analysis of relapse after mandibular advancement surgery. *J Oral Surg* 1978;9:676-84.
29. La Blanc JP, Turvey T, Epker BN, Hill C. Results following simultaneous mobilization of the maxilla and mandible for the correction of dentofacial deformities. *Oral Surg Oral Med Oral Pathol* 1982;54:607-12.
30. Epker BN, Wessberg G. Mechanisms of early skeletal relapse following surgical advancement of the mandible. *Br J Oral Surg* 1982;20:175-82.
31. Turvey T, Phillips C, Laytown HS, Proffit WR. Simultaneous superior repositioning of the maxilla and mandibular advancement. A report on stability. *Am J Orthod Dentofacial Orthop* 1988;94:372-83.
32. Schellhas KP, Piper MA, Bessette RW, Wilkes CH. Mandibular retrusion, temporomandibular joint derangement, and orthognathic surgery planning. *Plast Reconstr Surg* 1992;90:218-29.
33. Pancherz H, Anehus Pancherz M. The headgear effect of the Herbst appliance: a cephalometric long-term study. *Am J Orthod Dentofacial Orthop* 1993;103:510-20.
34. Akgül AA, Toygar TU. Natural craniofacial changes in the third decade of life: a longitudinal study. *Am J Orthod Dentofacial Orthop* 2002;122:512-22.
35. Tulloch JFC, Lenz BE, Phillips C. Surgical versus orthodontic correction for Class II patients: age and severity in treatment planning and treatment outcome. *Semin Orthod* 1999;5:231-40.
36. Flanary CM, Barnwell GM, Alexander JM. Patients' perceptions of orthognathic surgery. *Am J Orthod* 1985;88:137-45.
37. Mayo KH, Dryland-Vig KWL, Vig PS, Kowalski CJ. Attitude variables of dentofacial deformity patients: demographic characteristics and associations. *J Oral Maxillofac Surg* 1991;49:594-602.
38. Wilmot JJ, Barber HD, Chou DG, Vig KWL. Associations between severity of dentofacial deformity and motivation for orthodontic-orthognathic surgery treatment. *Angle Orthod* 1993;63:283-8.
39. Bell R, Kiyak HA, Joondeph DR, McNeill RW, Wallen TR. Perceptions of facial profile and their influence on the decision to undergo orthognathic surgery. *Am J Orthod* 1985;88:323-32.
40. Kiyak HA, McNeill RW, West RA, Hohl T, Heaton PJ. Personality characteristics as predictors and sequale of surgical and conventional orthodontics. *Am J Orthod* 1986;89:383-92.
41. Shell TL, Woods WG. Perception of facial esthetics: a comparison of similar Class II cases treated with attempted growth modification or later orthognathic surgery. *Angle Orthod* 2003;73:365-73.
42. Brons R. Chin corrections. In: Brons R, editor. Facial harmony. Standards for orthognathic surgery and orthodontics. London: Quintessence; 1998. 145-58.
43. Proffit WR, Turvey T, Moriarty JD. Augmentation genioplasty as an adjunct to conservative orthodontic treatment. *Am J Orthod* 1981;79:473-91.
44. Shiratsuchi Y, Kouno K, Tashiro H. Evaluation of masticatory function following orthognathic surgical correction of mandibular prognathism. *J Cranio Max Fac Surg* 1991;19:299-303.
45. Wolford LM, Reiche-Fischel O, Pushkar M. Changes in temporomandibular joint dysfunction after orthognathic surgery. *J Oral Maxillofac Surg* 2003;61:655-60.
46. Ruf S, Pancherz H. Does bite-jumping damage the TMJ? A prospective longitudinal clinical and MRI study of Herbst patients. *Angle Orthod* 2000;70:183-99.
47. Dolan P, White RP, Tulloch JFC. An analysis of hospital charges for orthognathic surgery. *Int J Adult Orthod Orthognath Surg* 1987;1:9-14.

48. Panula K, Keski-Nisula L, Keski-Nisula K, Oikarinen K, Keski-Nisula S. Costs of surgical-orthodontic treatment in community hospital care: an analysis of the different phases of treatment. *Int J Adult Orthod Orthognath Surg* 2002;17:297-306.
49. Thomas PM. Orthodontic camouflage versus orthognathic surgery in the treatment of mandibular deficiency. *J Oral Maxillofac Surg* 1995;53:579-87.
50. Kiyak HA, Bell R. Psychosocial considerations in surgery and orthodontics. In: Proffit WR, White RP, editors. *Surgical-orthodontic treatment*. Saint Louis: Mosby; 1990. 79-80.
51. Panula K, Oikarinen K, Finne K. Incidence of complications and problems related to orthognathic surgery: a review of 655 patients. *J Oral Maxillofac Surg* 2001;10:1128-37.
52. Gianni AB, Biglioli F, Bozzetti A, Brusati R. Neurosensory alterations of the inferior alveolar and mental nerve after genioplasty alone or associated with sagittal osteotomy of the mandibular ramus. *J Craniomaxillofac Surg* 2002;30:295-303.
53. Sameshima GT, Sinclair PM. Predicting and preventing root resorption. I. Diagnostic factors. *Am J Orthod Dentofacial Orthop* 2001;119:505-10.
54. Kaley J, Phillips C. Factors related to root resorption in the orthodontic practice. *Angle Orthod* 1991;61:125-32.

ON THE MOVE?

Send us your new address at least six weeks ahead

Don't miss a single issue of the journal! To ensure prompt service when you change your address, please photocopy and complete the form below.

Please send your change of address notification at least six weeks before your move to ensure continued service. We regret we cannot guarantee replacement of issues missed due to late notification.

JOURNAL TITLE:

Fill in the title of the journal here. _____

OLD ADDRESS:

Affix the address label from a recent issue of the journal here.

NEW ADDRESS:

Clearly print your new address here.

Name _____

Address _____

City/State/ZIP _____

INDIVIDUAL SUBSCRIBERS

COPY AND MAIL THIS FORM TO:

Elsevier Inc.
Subscription Customer Service
6277 Sea Harbor Dr
Orlando, FL 32887

OR FAX TO:

407-363-9661

OR E-MAIL:

elspcs@elsevier.com

OR PHONE:

800-654-2452

Outside the U.S., call

407-345-4000