



**Class II Skeletal, Class II(I) Dental, Long Anterior Lower Face Height, Maxillo - mandibular dental protrusion, Crowding**





**KEVIN HAINES**  
**AGE: 12.6**



**Active Treatment - 4 years**

Adrian J Palencar, MUDr, MAGD, IBO, FADI, FPFA, FICD

**Kevin Haines, age 12.6**  
Class II skeletal, Class II(I) dental  
Treatment started - March 08, 2007  
Treatment finished - March 2, 2011  
Active Treatment: 4 years

Adrian J. Palencar, MUDr, MAGD, IBO, FADI, FPFA, FICD



This is to certify that  
Dr. Adrian Palencar  
Has won **FIRST PLACE** in the  
2011 IAO Annual Meeting  
Case Displays  
April 9, 2011  
Scottsdale Plaza Resort  
Scottsdale, Arizona USA

The bearer is entitled to \$100  
reimbursement for any  
IAO Certified Instructor Course  
or the 2011 IAO Annual Meeting


Please send a copy of this certificate and a receipt for  
the course to the IAO headquarters office. The IAO  
will reimburse the bearer.

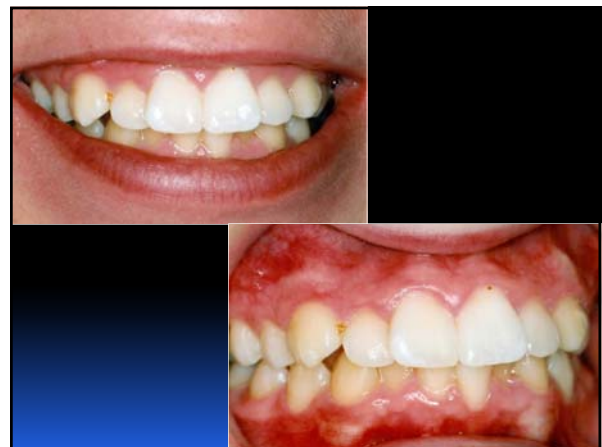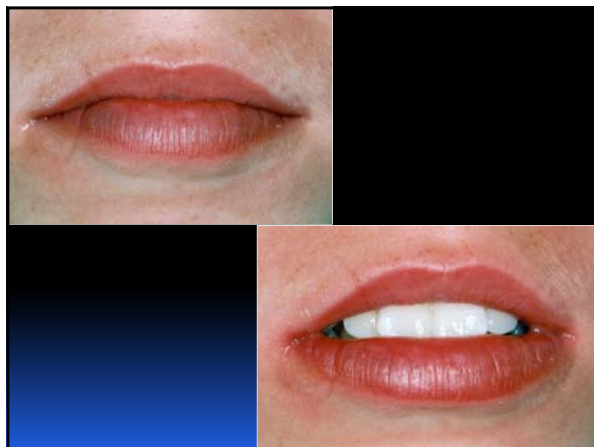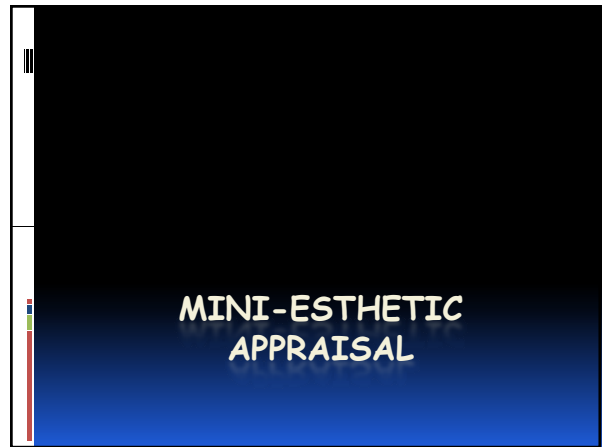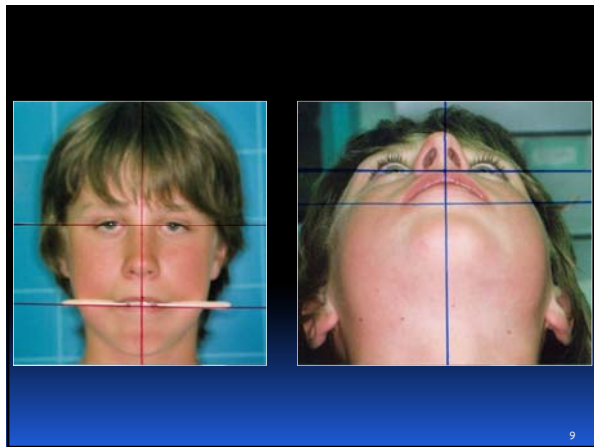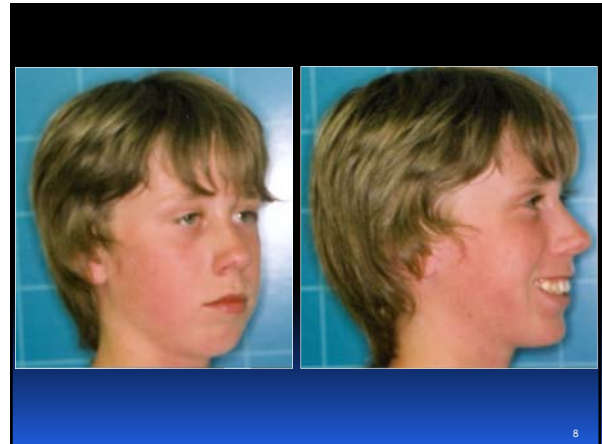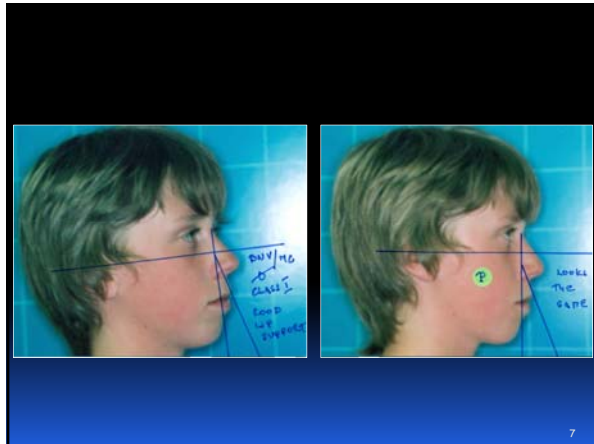This certificate is good until April 19, 2012.

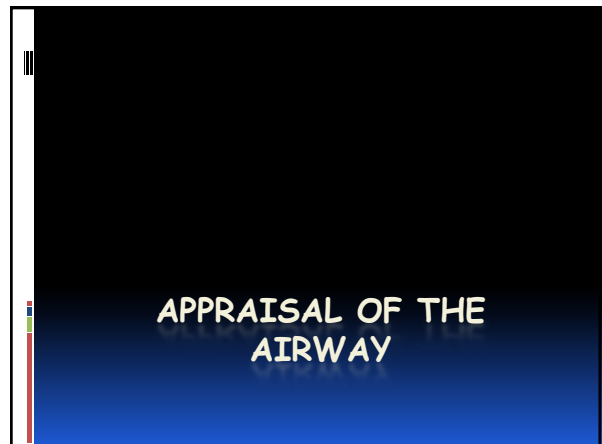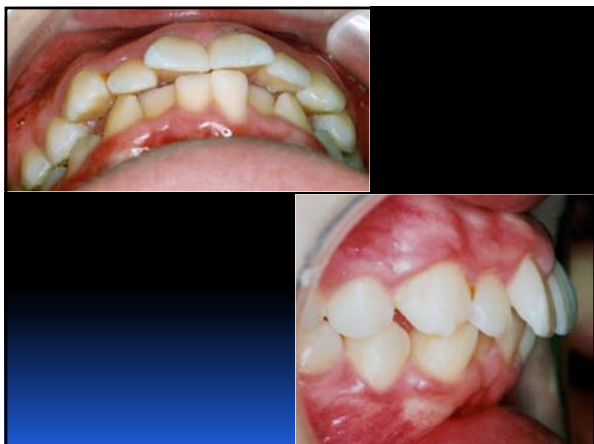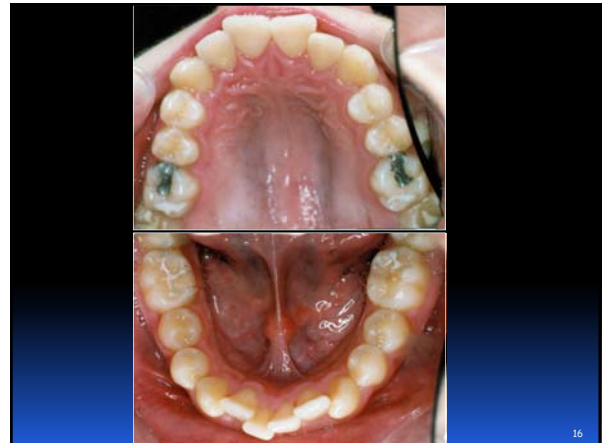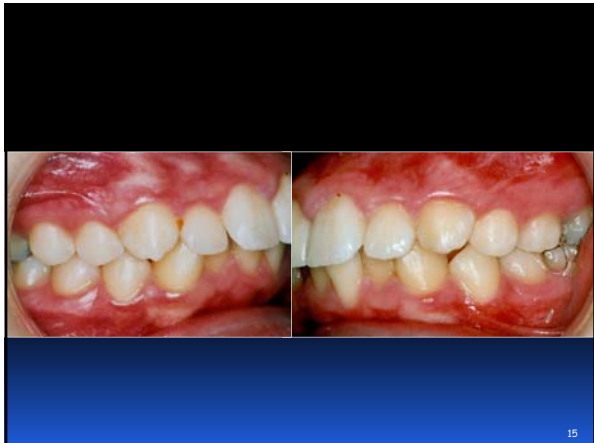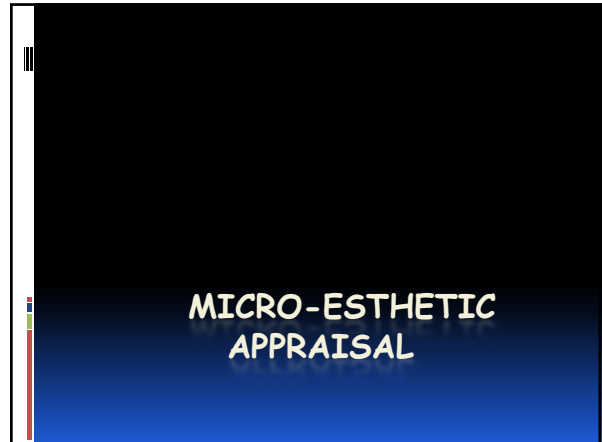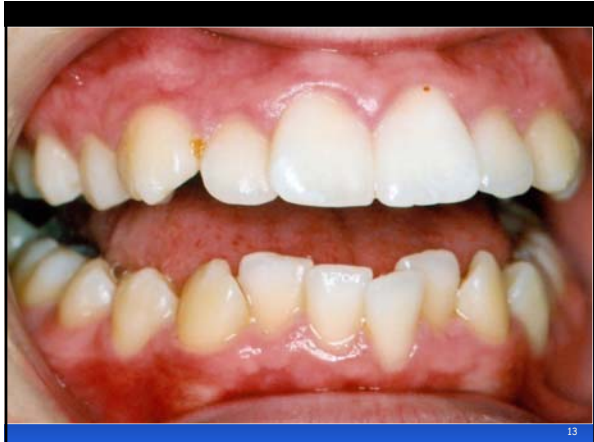**MACRO-ESTHETIC APPRAISAL**

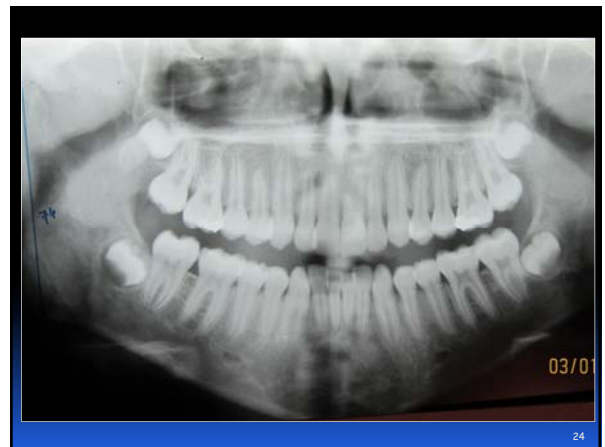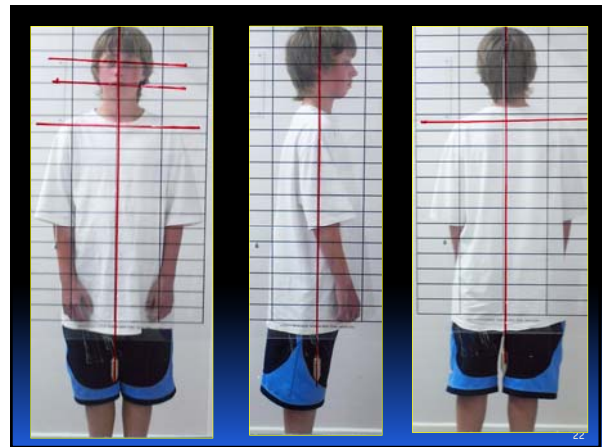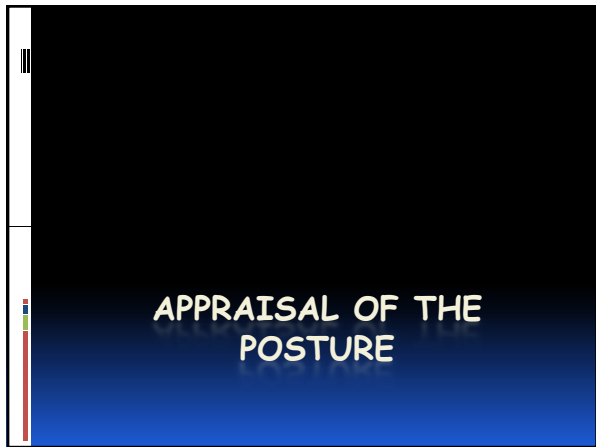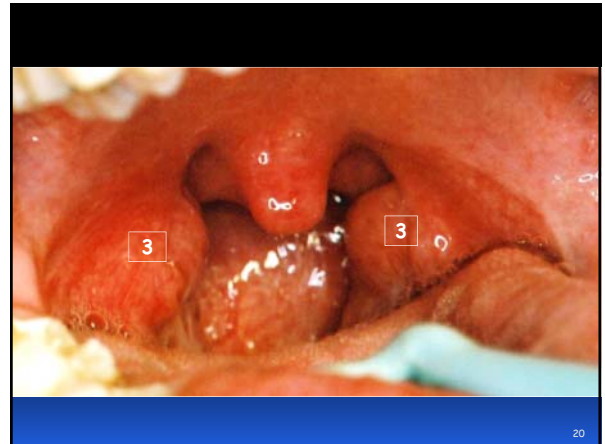
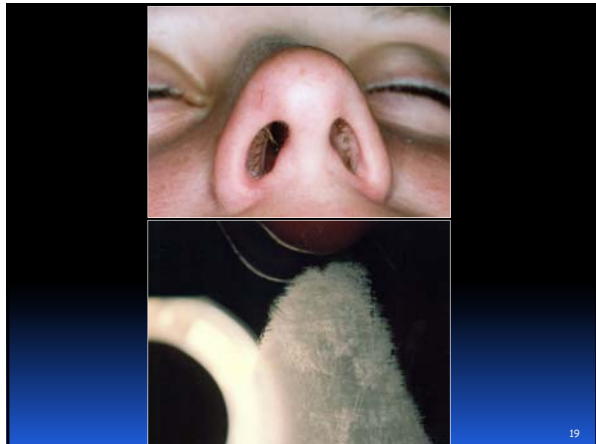


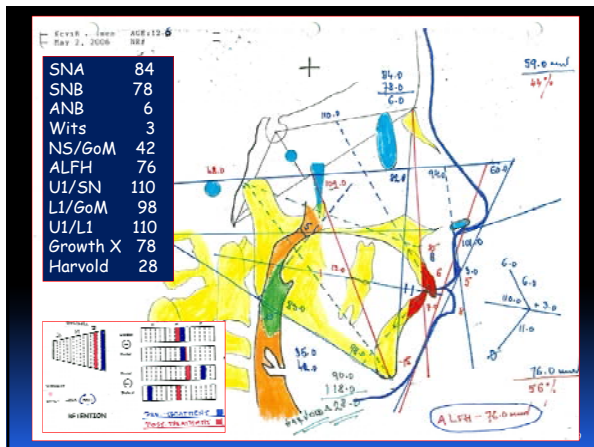
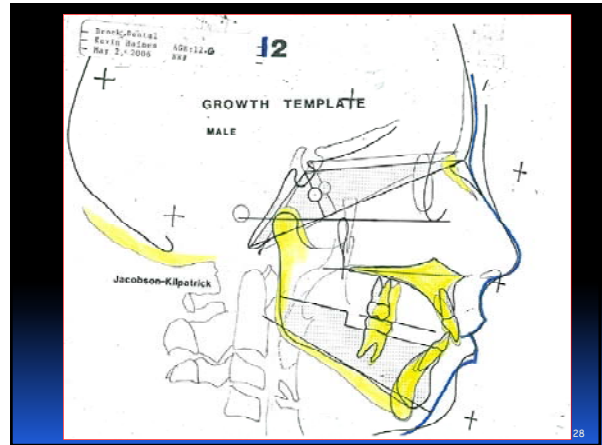
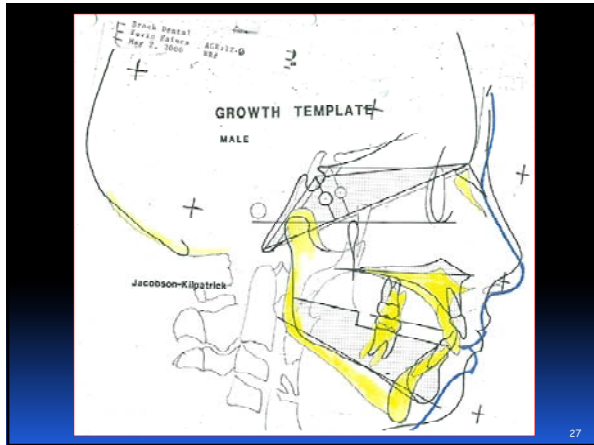
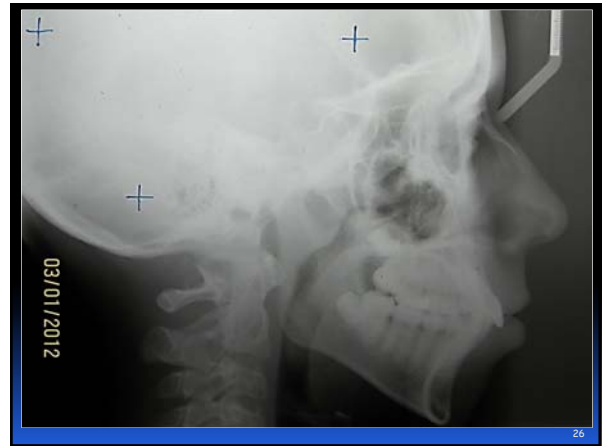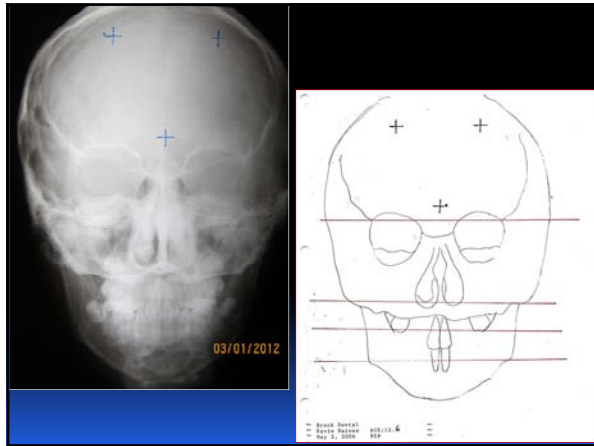
Measurements:  
24  
5  
28  
19











Dr. Adrian J. Palencar

ANALYSIS OF TOOTH SIZE DISCREPANCIES

ANTERIOR RATIO

Sum Mandibular 6 teeth  $\frac{41}{51}$  mm. Mean 77.2

Sum Maxillary 6 teeth  $\frac{51}{51}$  mm. Anterior Ratio Range 74.5-80.4

Maxillary 6	Mandibular 6	Maxillary 6	Mandibular 6	Maxillary 6	Mandibular 6
40.0	39.0	45.5	35.1	50.5	39.0
40.5	31.3	46.0	35.5	51.0	39.4
41.0	31.7	46.5	35.9	51.5	39.8
41.5	32.0	47.0	36.3	52.0	40.1
42.0	32.4	47.5	36.7	52.5	40.5
42.5	32.8	48.0	37.1	53.0	40.9
43.0	33.2	48.5	37.4	53.5	41.3
43.5	33.6	49.0	37.8	54.0	41.7
44.0	34.0	49.5	38.2	54.5	42.1
44.5	34.4	50.0	38.6	55.0	42.5
45.0	34.7				

If anterior ratio exceeds 77.2:  $\frac{41}{51} = \frac{78.6}{77.2}$  Excess Mandibular 6

If anterior ratio is less than 77.2: Correct Maxillary 6 Excess Maxillary 6

The sum of the mandibular 6 teeth is 36 mm. The tables show that when the mandibular 6 anterior teeth have a mesiodistal width of 36 mm, the ideal width for the maxillary 6 anterior teeth should be 46.7 mm.

Kevin Haines, age: 12.6 Dr. A. J. Palencar

**DIAGNOSES**  
 Skeletal: Class II, long ALPH  
 Dental: Class II, Division 1, Crowding  
 Functional: TAD: See the history.  
 Airway: Narrow airway, enlarged tonsils #3, adenoid area 5.0 mm  
 Habits: Mouth breathing  
 Profile: Convex  
 Lips: Convex

**TREATMENT**  
 Referral to ENT - Tonsils and Adenoids  
 The patient may need removal of some permanent teeth  
 1) MX Transverse development with pads (removable or fixed)  
 2) MX Bowbeer appliance, MX Trans - palatal arch with large button and HP Head gear  
 3) SWA  
 4) MX QCM Removable Retainer, MX Bonded retainers  
 ODS FSW from #43, 4, 41, 31, 32, 33 - INDEFINITE

RETENTION

31

**BROCK DENTAL** Dental care for your entire family in the heart of Niagara  
 Dr. Adrian J. Palencar, M.D.  
 Dr. Say Chuan Hoang, D.D.S.

May 16, 2006  
 Dear Doctor,  
 Kevin Haines, Age 12.6

The clinical and Cephalometric evaluation of my orthodontic patient Kevin Haines reveals habitual mouth breathing and narrow maxillopharyngeal area. Adenoids are enlarged, restricting the airway to only 5.0 mm. (the norm for his age is 8.0 with the standard Deviation 4.1 mm). Kevin has a Long Lower Face syndrome. He has also enlarged tonsils - size 3.

In the view of the above, I would appreciate a thorough medical evaluation of Kevin's airway (possibly referral to an ENT specialist). I am looking forward to your opinion and recommendations.

Enclosed please kindly find the pamphlet "Airway, the key to early facial growth and malocclusion".

Thank you in advance.

Respectfully,  
 Adrian J. Palencar, M.D., M.A.B.D., IBO, F.A.O.

3250 Schuman Place, #4, Thorold, ON L2V 4Y9, Canada • Ph: 905.641.9850 • Fax: 905.641.9908

32

**BROCK DENTAL** Dental care for your entire family in the heart of Niagara  
 Dr. Adrian J. Palencar, M.D.  
 Dr. Say Chuan Hoang, D.D.S.

May 17, 2006  
 Dear Mr. & Mrs. Haines  
 Kevin Haines, age 12.6  
 I have just done an examination and orthodontic work up on Kevin and the following are my findings:

**DIAGNOSES:**  
 • SKELETAL: Class II, Long Lower Face  
 • DENTAL: Class II, Division 1, Crowding  
 • FUNCTIONAL: TAD: See the history  
 Airway: Narrow airway, adenoid area - only 5.0 mm wide, enlarged tonsils #3  
 Habits: Mouth breathing  
 • PROFILE: Retrognathic  
 • LIPS: Convex

**TREATMENT:** Referral to ENT, enlarged tonsils  
 1) MX - Transverse development with pads (removable or fixed)  
 2) MX - Bowbeer appliance, MX Trans - palatal arch with large button and HP Head gear  
 3) SWA - braces  
 Retention: MX - QCM removable retainer, MX bonded retainers ODS FSW to #43, 42, 41, 31, 32, 33. Indefinite retention

Treatment time, approximately 30 months pending Kevin's cooperation.  
 Fee: for the orthodontic treatment is a \$4200.00 - Laboratory fee to be paid @ \$100.00 + lab per month with no interest. VISA or MASTER CARD is preferred.  
 There will be an additional fee of the end of the treatment for any extra X-rays, waxing and polishing.  
 Maximum cooperation, excellent oral hygiene and avoidance of hard, brittle, sticky and smelly food are required for the successful result. Brushing with a fluoridated mouth wash daily is recommended.  
 Very difficult cases because of the narrow airway and long lower face. The airway has to be corrected, otherwise, the case will relapse.

I have read and understood the content of this page

Respectfully yours,  
 Adrian J. Palencar, M.D., M.A.B.D., IBO, F.A.O. Date: June 7, 2006

3250 Schuman Place, #4, Thorold, ON L2V 4Y9, Canada • Ph: 905.641.9850 • Fax: 905.641.9908

33

**Bonded Hyrax**

34

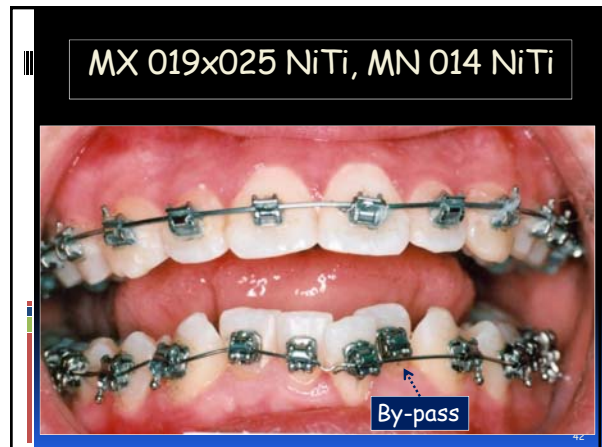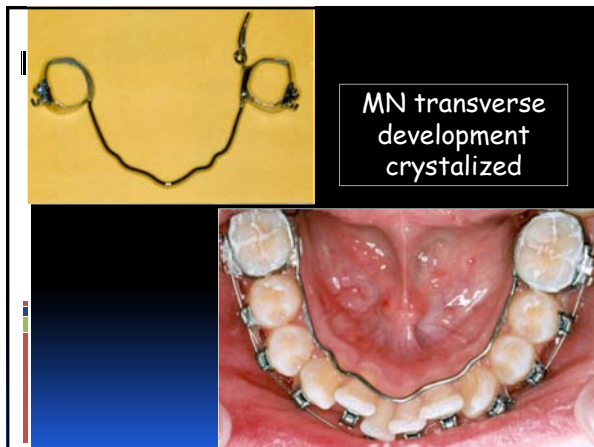
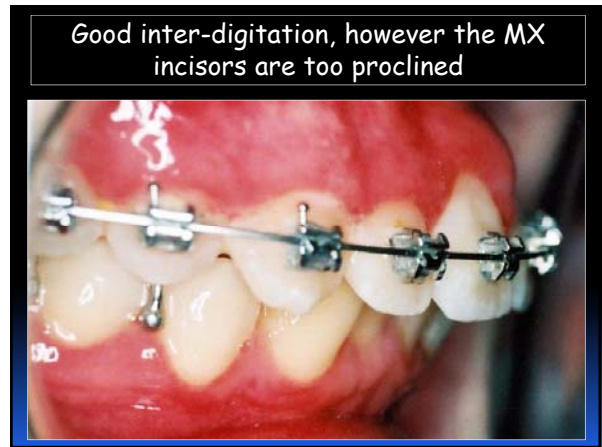
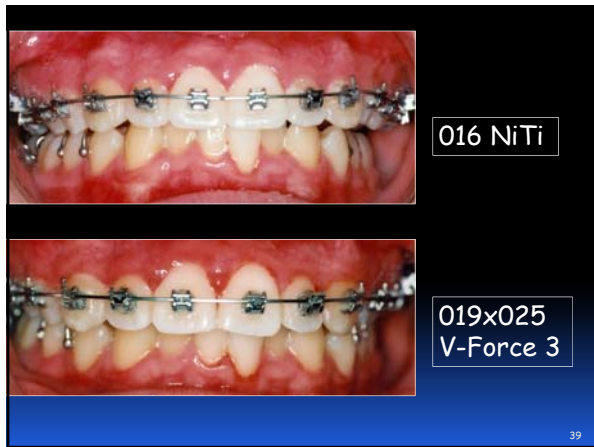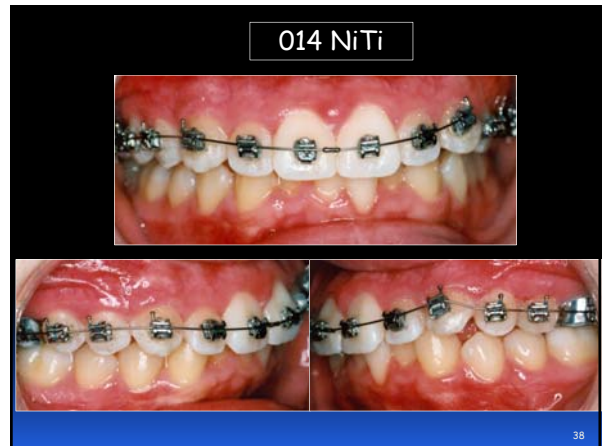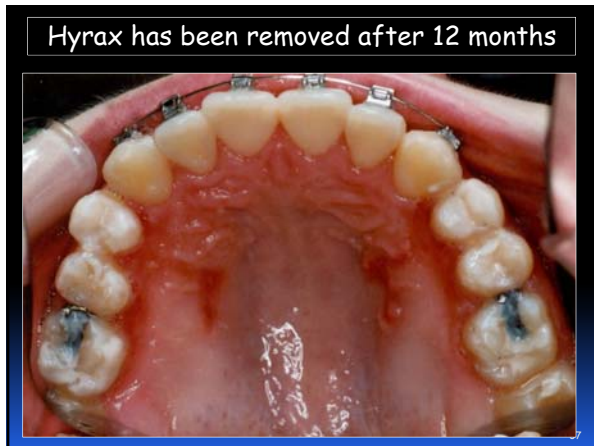**Bowbeer Appliance**

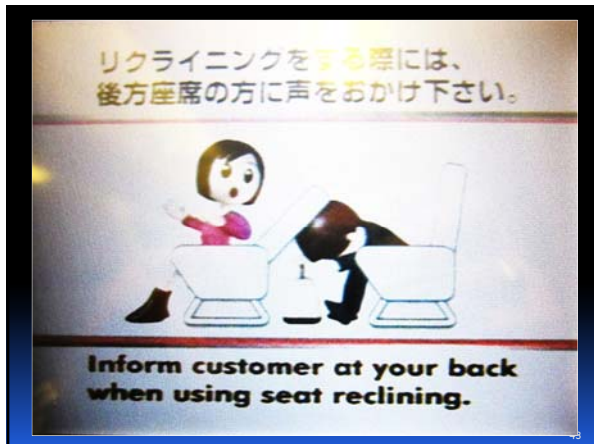35

**014 NiTi**


**016 SS**

36





**AFTER 18 MONTH OF TREATMENT, THE PARENTS, PATIENT AND THE CLINICIAN AGREED THAT FOUR BICUSPIDS HAVE TO BE EXTRACTED**



**MX 018x025 SS, MN 018 SS, Step Down, 1/4" - 4.5 oz. Elastics**

**MN 1<sup>st</sup> bicuspid were excised**

**MX & MN 018 SS, Step up and Step down, 1/4" - 4.5 oz. Elastics**

**MN 1<sup>st</sup> bicuspid and left 2<sup>nd</sup> molar were excised**

**Titration of force level with the CORREX gram gage**



**MX 018 SS, MN 016 NiTi Stopped Retraction of MX Right Cuspid and MN left Cuspid**



49

**DR. ADRIAN PALENCAR**  
3282 South Avenue, Suite 4, Scotch Plains, NJ 07076  
Tel: 908.262.2828 Fax: 908.262.2828

**INFORMED CONSENT FOR AIR-ROTOR SLENDERIZING**

I give my consent to Dr. Palencar to perform Air-Rotor Slenderizing (ARS) on my (my child's) teeth. It has been explained to me (to my child) to the extremity as well as alternative treatments or the repercussions of no treatment at all. I have had opportunity to ask questions. I understand that ARS is an irreversible procedure. I also understand that a small amount of interproximal enamel will be removed between the teeth with a high-speed drill to create a space for correction of crowding. This procedure is most of the time painless and doesn't require anesthesia.



I understand that I (my child) should maintain impeccable oral hygiene and I (my child) will apply topical fluoride given to me (my child) after each visit.

DATE: June 22/17

Name of patient: Kieran Houser  
Signature of patient: [Signature]  
Signature of witness: [Signature]

**ARS RECORD**

DRAIN ASSESS:



Slenderized 2.2 mm (Bolton discrepancy) on the right side, to shift the midline

50

**MX & MN 018 SS, Midlines are Approximating**



51

**Oral Hygiene Appraisal**



52

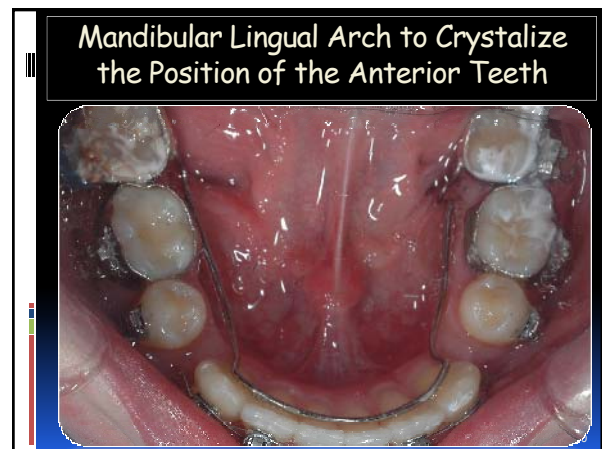
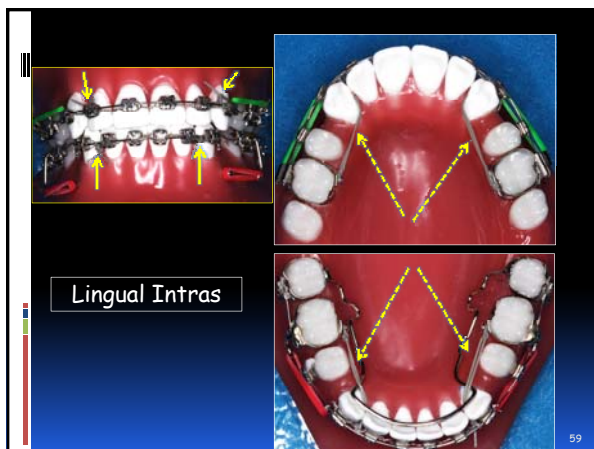
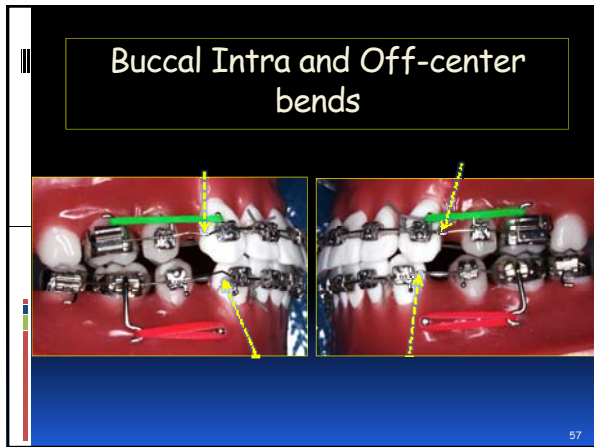
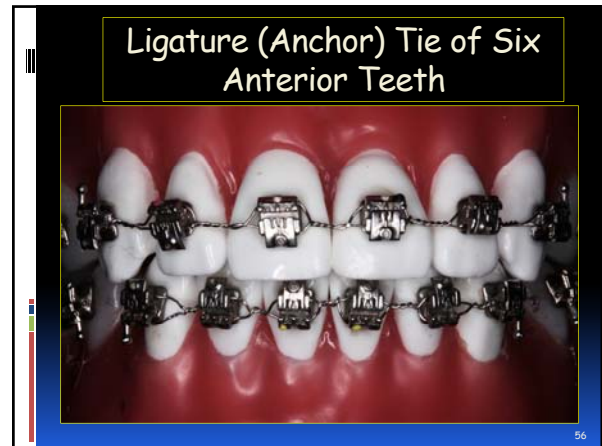
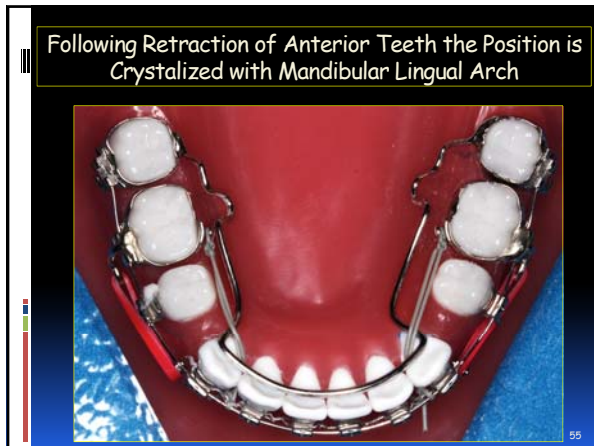
**Appraisal of Maxillary and Mandibular Dental Protrusion**

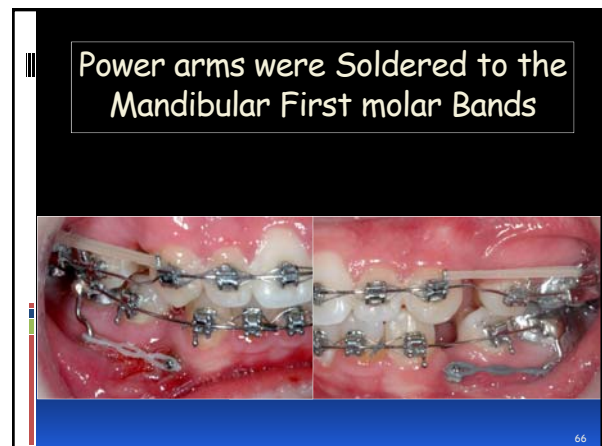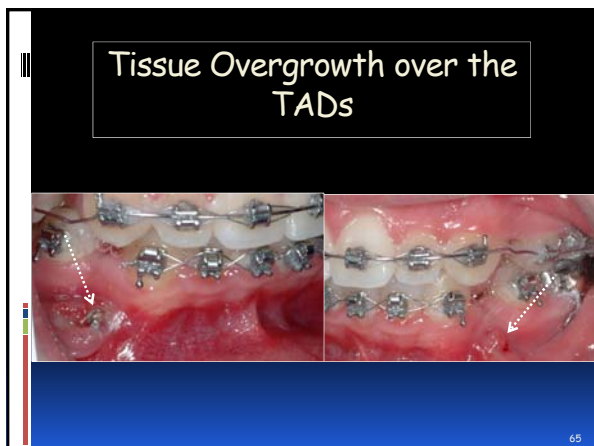
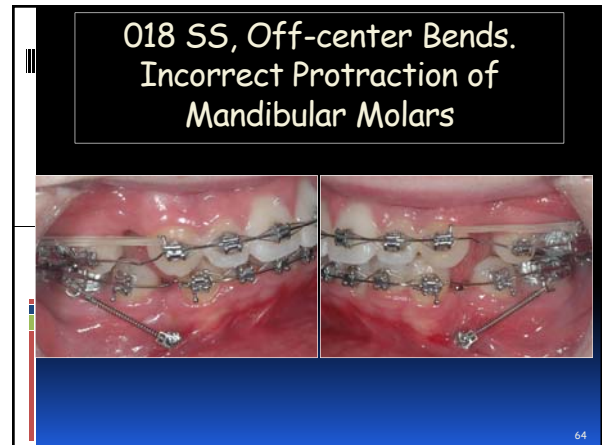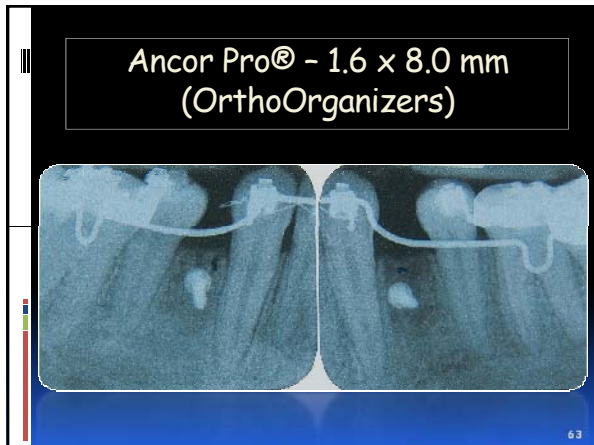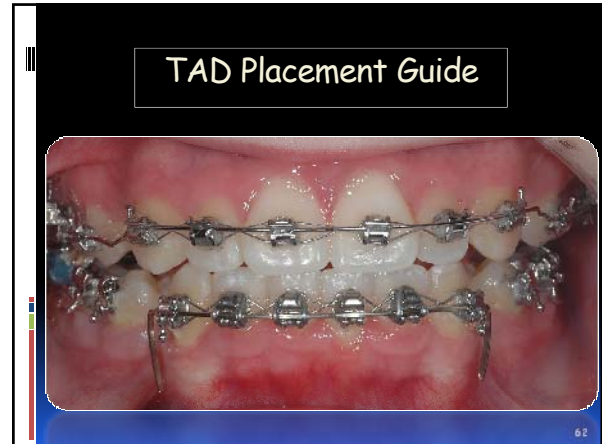


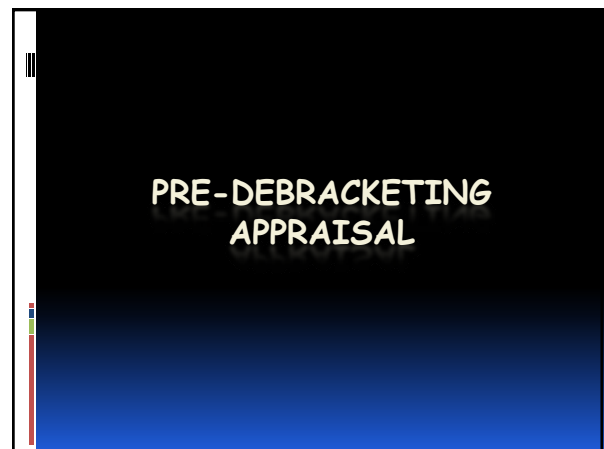
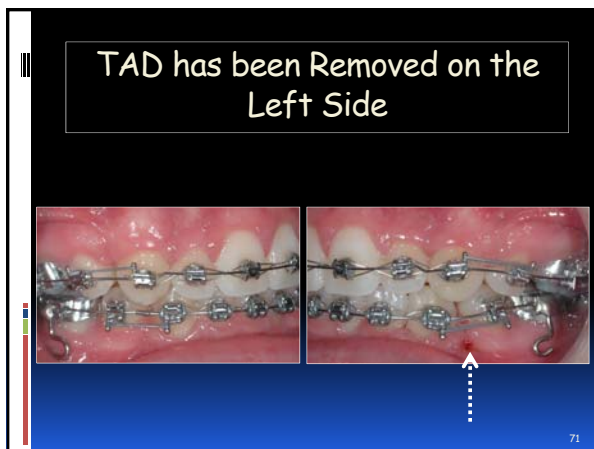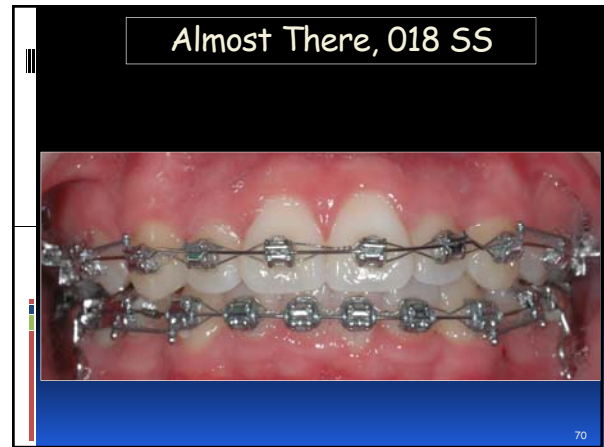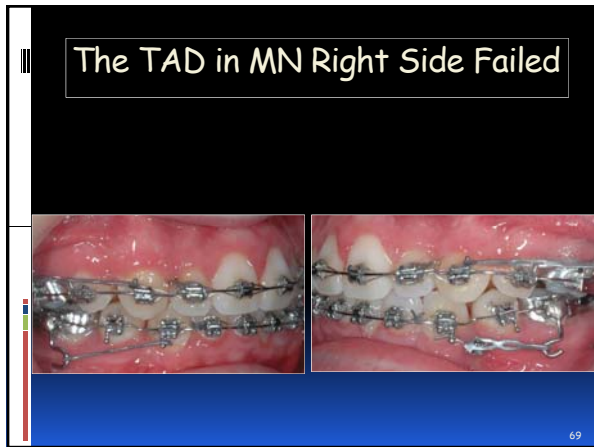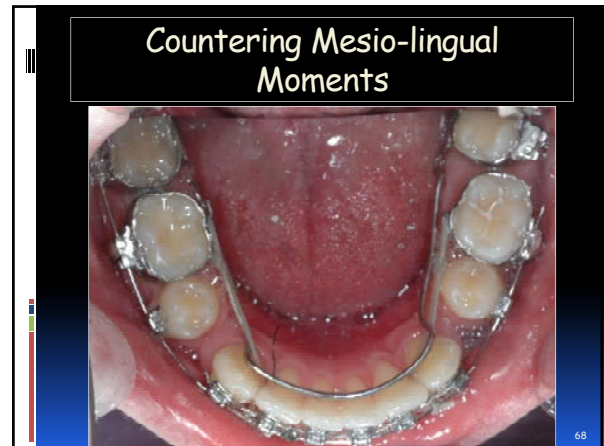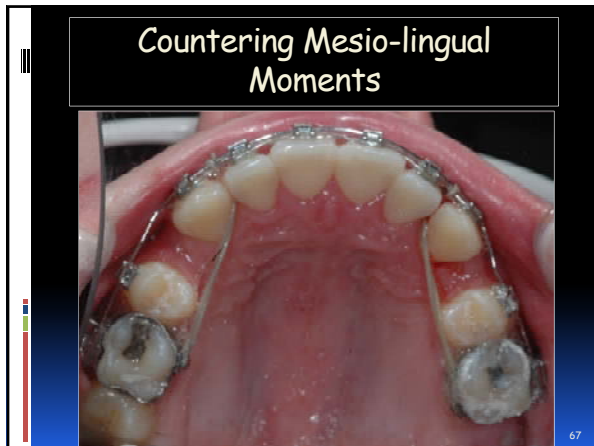Off-center bend

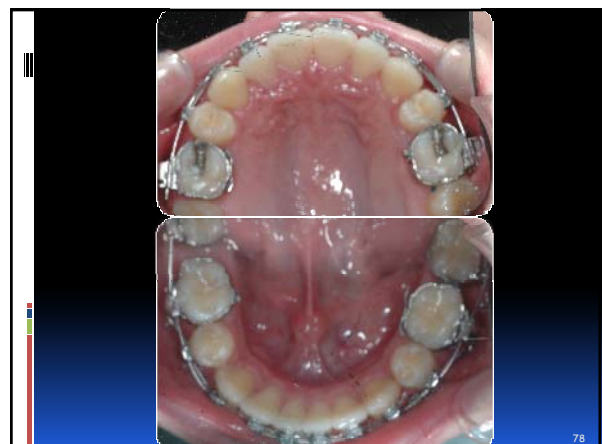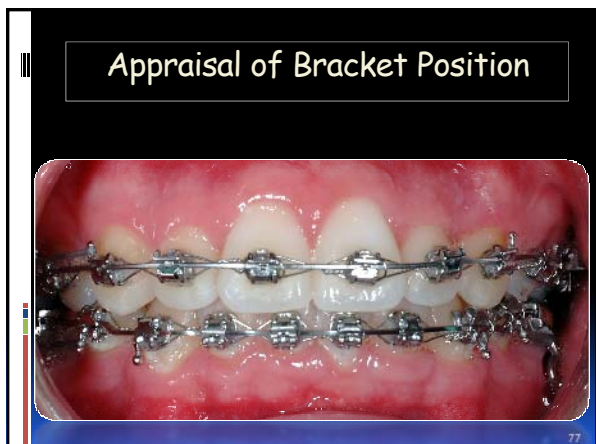
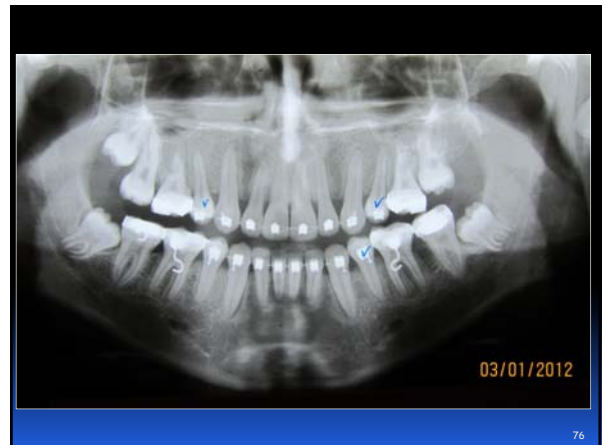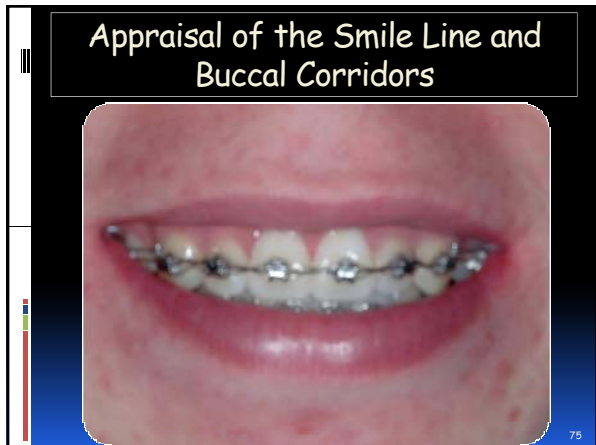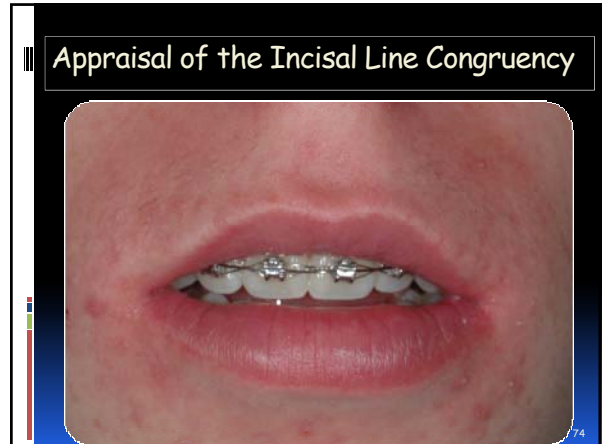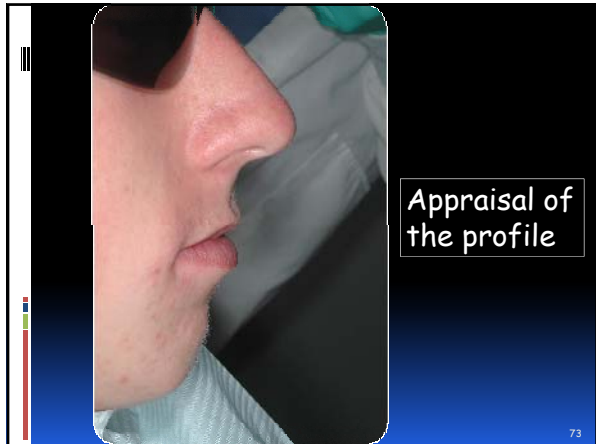**Patient and parents found the lips competent and the convexity pleasing**

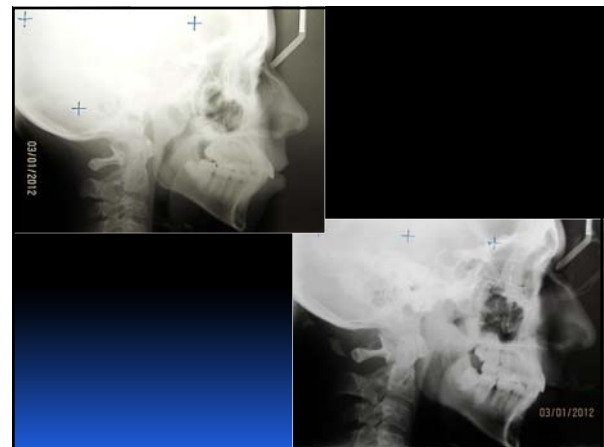
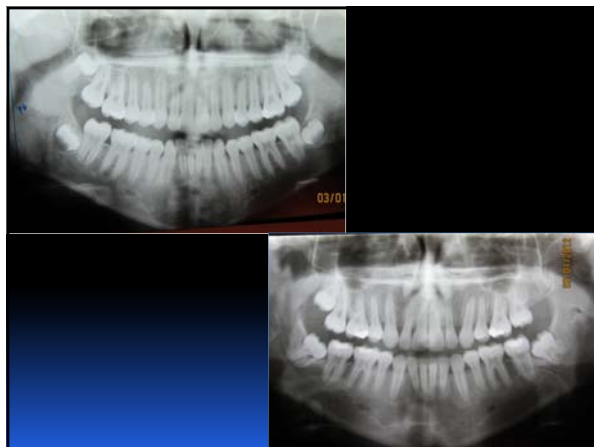
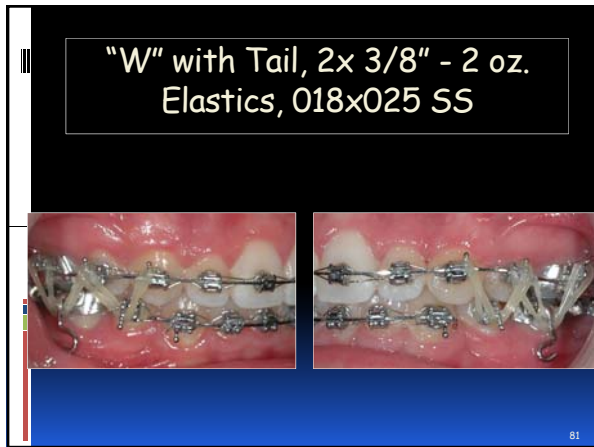
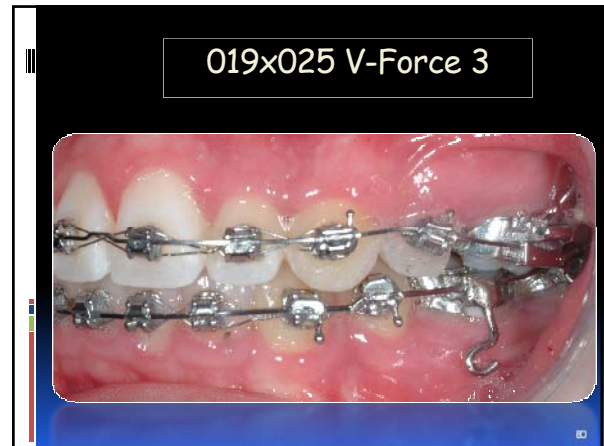
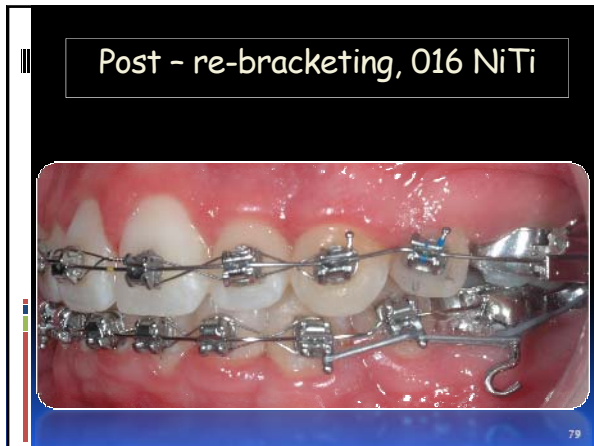







	2006	2011
SNA	84	81
SNB	78	77
ANB	6	4
Wits	3	2
NS/GoM	42	35
ALFH	76	75
U1/SN	110	118
L1/GoM	98	93
U1/L1	110	117
Growth X	78	81
Harvold	28	35

RETENTION

EXTRACTED

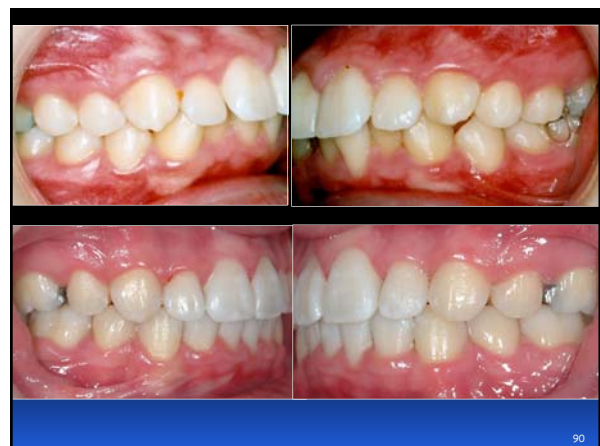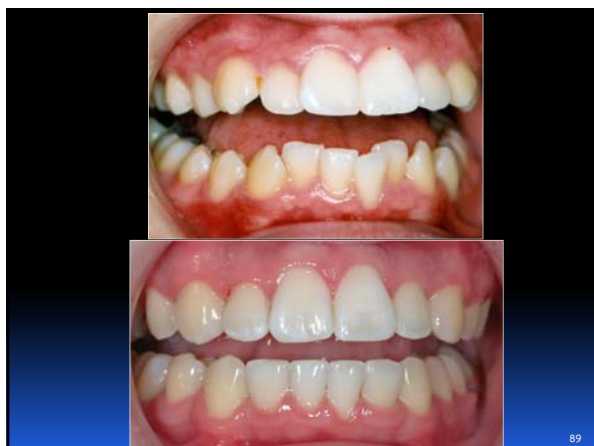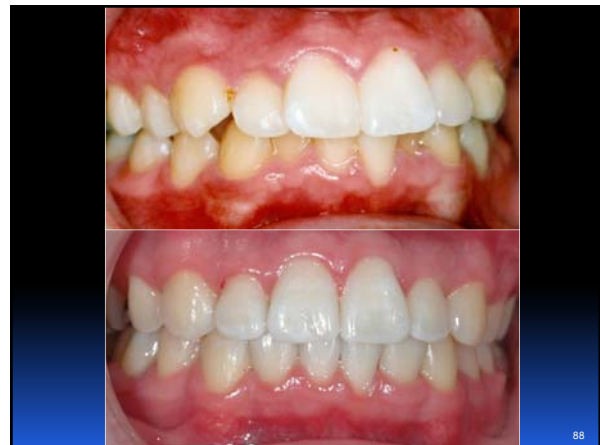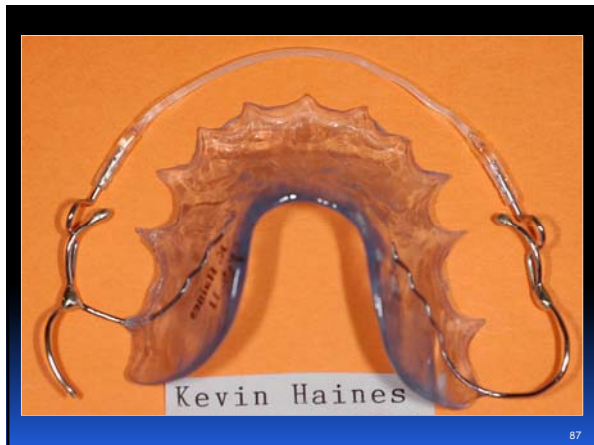POST-EXTRACTED

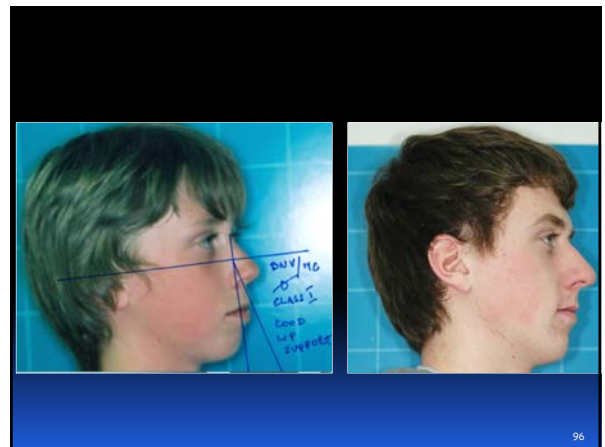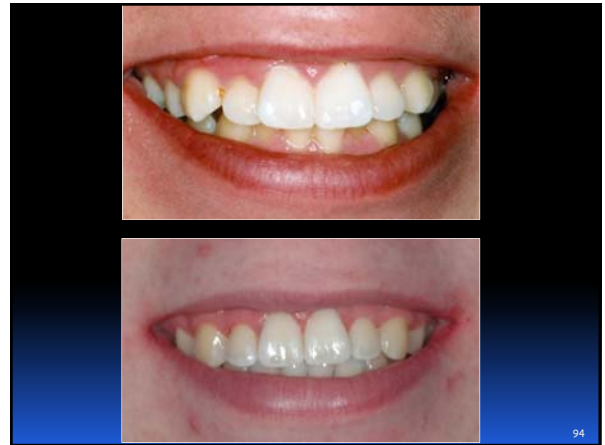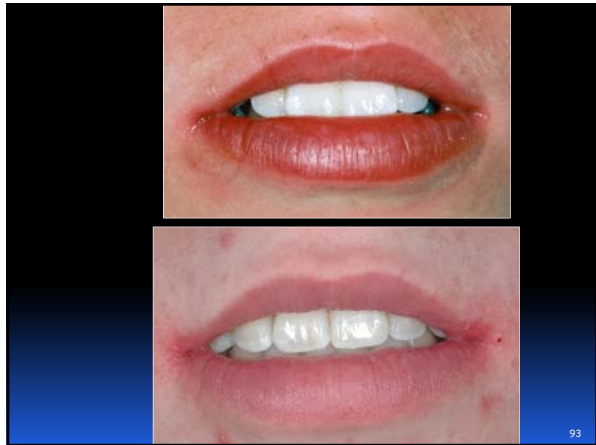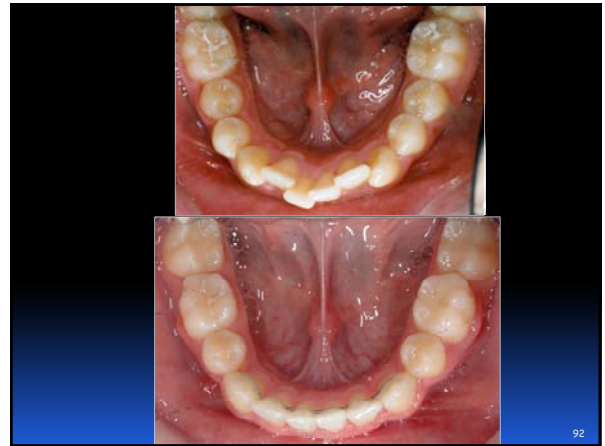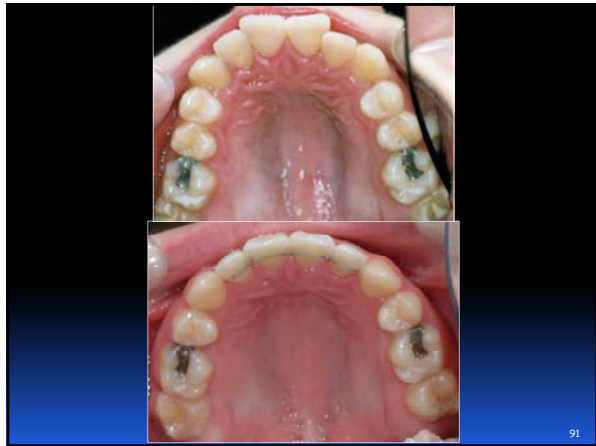Kevin Haines

MAY 2, 2006 ———— ABO: 14.6

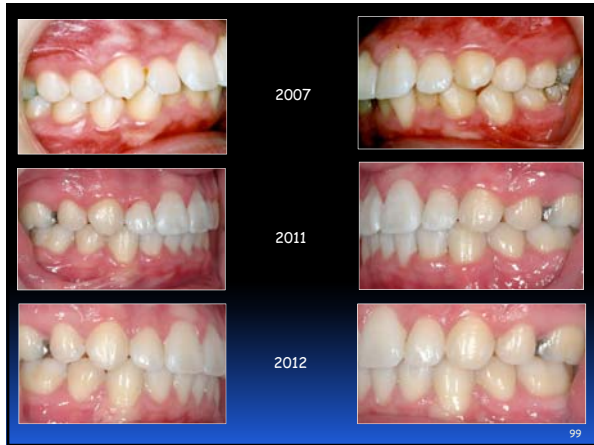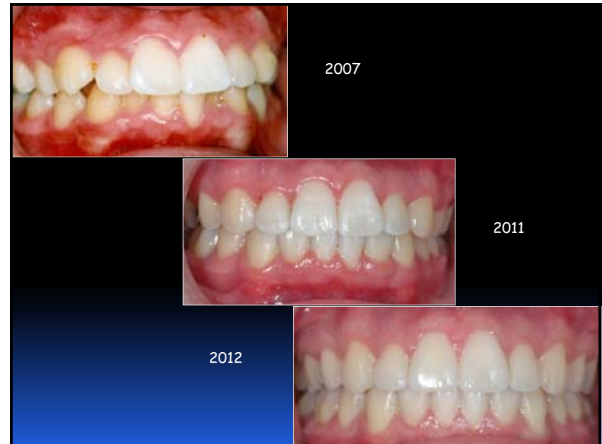FEB 4, 2009 ———— ABO: 16.3

MARCH 2, 2011 ———— ABO: 17.4









**"GOD DOESN'T ASK YOU TO SUCCEED, JUST TO TRY"**

Mother Theresa of Calcutta

